




Isolated anterior cerebral artery occlusion:
an atypical form of moyamoya diseaseSi-Meng Liu,^{1,2,3} Gan Gao,^{1,2,3} Fang-bin Hao,^{1,2,3} Shi-tong Liu,^{1,2,3} Ri-miao Yang,^{1,2} Hou-di Zhang,^{1,2} Min-Jie Wang,^{1,2,3} Zheng-xing Zou,^{1,2} Dan Yu,^{1,2} Qian Zhang,^{1,2} Qing-Bao Guo,^{1,2,3} Xiao-Peng Wang ,^{1,2,3} He-guan Fu,^{1,2} Jing-Jie Li,^{1,2,3} Cong Han ,^{1,2} Lian Duan ^{1,2}

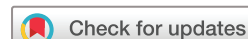To cite: Liu S-M, Gao G, Hao F, et al. Isolated anterior cerebral artery occlusion: an atypical form of moyamoya disease. *Stroke & Vascular Neurology* 2024;0. doi:10.1136/svn-2023-002992

► Additional supplemental material is published online only. To view, please visit the journal online (<https://doi.org/10.1136/svn-2023-002992>).

S-ML, GG and F-BH contributed equally.

S-ML, GG and F-BH are joint first authors.

Received 21 November 2023
Accepted 7 February 2024



© Author(s) (or their employer(s)) 2024. Re-use permitted under CC BY-NC. No commercial re-use. See rights and permissions. Published by BMJ.

¹Department of Neurosurgery, the First Medical Center of Chinese PLA General Hospital, Beijing, China

²Department of Neurosurgery, the Fifth Medical Center of Chinese PLA General Hospital, Beijing, China

³Medical School of Chinese PLA, Beijing, China

Correspondence to

Professor Lian Duan;
duanlian307@sina.com

Professor Cong Han;
hc82225@126.com

ABSTRACT

Background The relationship between anterior cerebral artery (ACA) occlusion and moyamoya disease (MMD) has rarely been studied. In this study, we focused on a special type of MMD: isolated ACA-occlusive MMD. We investigated clinical attributes, genotypes and progression risk factors in patients with ACA-occlusive MMD, providing initial insights into the relationship between ACA occlusion and MMD.

Methods We retrospectively analysed digital subtraction angiography (DSA) from 2486 patients and diagnosed 139 patients with ACA-occlusive MMD. *RNF213* p.R4810K (rs112735431) mutation analysis was performed. Patients were categorised into progression and non-progression groups based on whether they progressed to typical MMD. Differences in clinical characteristics, neuropsychological assessment, radiological findings and genotypes were evaluated. Logistic regression analyses identified risk factors for ACA-occlusive MMD progression.

Results The median age of patients with ACA-occlusive MMD was 36 years, and the primary symptom was transient ischaemic attack (TIA). 72.3% of ACA-occlusive MMD patients had cognitive decline. Of 116 patients who underwent *RNF213* gene mutation analysis, 90 patients (77.6%) carried the *RNF213* p.R4810K GG allele and 26 (22.4%) carried the GA allele. Of 102 patients with follow-up DSA data, 40 patients (39.2%) progressed. Kaplan-Meier curve estimates indicated a higher incidence of ischaemic stroke in the progression group during follow-up ($p=0.035$). Younger age ($p=0.041$), *RNF213* p.R4810K GA genotype ($p=0.037$) and poor collateral compensation from the middle cerebral artery (MCA) to ACA ($p<0.001$) were risk factors of ACA-occlusive MMD progression to typical MMD.

Conclusions Cognitive decline and TIA might be the main manifestations of ACA-occlusive MMD. Isolated ACA occlusion may be an early signal of MMD. The initial lesion site of MMD is not strictly confined to the terminal portion of the internal carotid artery. Younger patients, patients with *RNF213* p.R4810K GA genotype or those with inadequate MCA-to-ACA compensation are more likely to develop typical MMD.

INTRODUCTION

As one of the main intracranial blood supply arteries, anterior cerebral artery (ACA) occlusion currently receives less attention.¹ The reported incidence of isolated ACA territory

WHAT IS ALREADY KNOWN ON THIS TOPIC

⇒ Previous studies have shown that non-atherosclerotic isolated middle cerebral artery occlusion might be an early manifestation of moyamoya disease (MMD). However, whether non-atherosclerotic isolated anterior cerebral artery (ACA) occlusion is one of the early manifestations of MMD is not yet described. And whether there are differences in early-onset forms of MMD remains unclear.

WHAT THIS STUDY ADDS

⇒ Isolated non-atherosclerotic ACA occlusion might serve as an early indicator of MMD and has the potential to progress to typical MMD. Cognitive decline and transient ischaemic attack (TIA) might be the main manifestations of ACA-occlusive MMD. Age, GA genotype of *RNF213* p.R4810K and MCA-to-ACA compensations are correlation factors for disease progression.

HOW THIS STUDY MIGHT AFFECT RESEARCH, PRACTICE OR POLICY

⇒ Since the original definition of MMD was based on radiology, this study provides groundbreaking insights into the nuances of early manifestation and progression of MMD, challenging traditional clinical paradigms. The comprehensive evaluation of isolated non-atherosclerotic ACA occlusion and its potential relationship with MMD will enrich the repository on cerebrovascular research.

infarction ranges from 0.6% to 3% of all cases of ischaemic stroke.^{2,3} However, due to the atypical and silent manifestations of ACA infarction, the incidence of ACA occlusion could be underdiagnosed and underestimated. The aetiological mechanism of ACA occlusion varies greatly among individuals and is mainly related to atherosclerosis,⁴ in situ thrombosis, cardiogenic embolism⁵ or moyamoya disease (MMD).⁶

MMD is a chronic progressive cerebrovascular disease characterised by bilateral stenosis or occlusion at the terminal portion of the internal carotid artery (ICA) or the proximal sections of the ACA and/or middle cerebral artery (MCA), accompanied by the formation

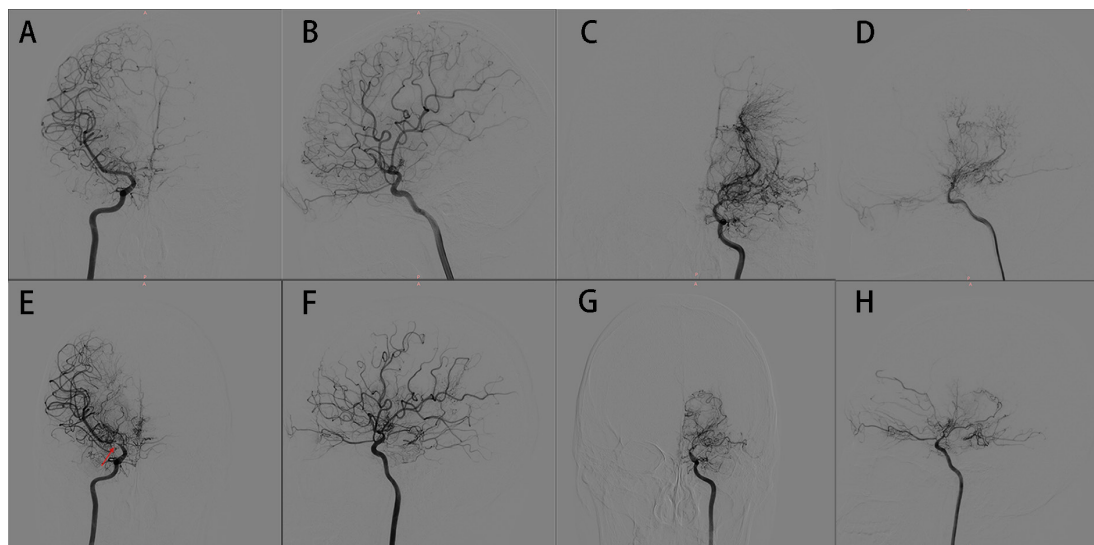


Figure 1 Digital subtraction angiography (DSA) of anterior cerebral artery (ACA)-occlusive moyamoya disease. (A–D) DSA results at the first admission. As shown in images (A) and (B), only the ACA was occluded in the right cerebral hemisphere; the middle cerebral artery (MCA) was not involved. Images (C) and (D) show intracranial vascular lesions in the contralateral cerebral hemisphere. The terminal portion of the internal carotid artery in the contralateral cerebral hemisphere was occluded, and the posterior communicating artery was open, accompanied by the formation of abnormal vascular networks. (E–H) DSA review 1 year after the first admission. As shown by the arrow in image (E), the MCA on the isolated ACA occlusion side (right cerebral hemisphere) showed stenosis and abnormal vascular networks.

of abnormal vascular networks at the base of the brain.^{7–9} Unlike typical MMD, we have identified a distinct variant uniquely characterised by proximal occlusion of the ACA on one side, with no lesions on the ipsilateral side of ICA and MCA (figure 1). However, a precise definition for patients displaying typical moyamoya-like vessels on one side in conjunction with an isolated ACA occlusion on the contralateral side remains absent from the current diagnostic criteria. No previous studies have categorised or described such diseases. To address this gap, we have identified these patients as having ACA-occlusive MMD.

Isolated ACA occlusion has unique clinical features, such as akinetic mutism, aphasia and cognitive decline.¹⁰ The treatment of vascular occlusion caused by MMD is different from that caused by other aetiologies, and conventional surgical revascularisation treatment for MMD does not always directly benefit the ACA blood supply territory. Therefore, it is meaningful to study the clinical features, genetic background and natural history of patients with ACA-occlusive MMD. We also evaluated risk factors contributing to ACA-occlusive MMD progression and attempted to elucidate the relationship between ACA occlusion and MMD.

METHODS

Study population

We conducted a retrospective analysis of digital subtraction angiography (DSA) data from 2486 patients admitted to our department from January 2015 to December 2019. Based on DSA results, 186 patients developed isolated ACA occlusion in at least one cerebral hemisphere.

Finally, 139 patients were diagnosed with ACA-occlusive MMD based on inclusion and exclusion criteria.

We rigorously applied our inclusion criteria through both DSA and high-resolution magnetic resonance imaging (HR-MRI). Only patients with ACA occlusion were included; patients with ACA stenosis were not included in our study. Diagnostic criteria of ACA-occlusive MMD included unilateral occlusion of the ACA's proximal portions, no lesions in the ipsilateral MCA and typical MMD manifestations in the contralateral cerebral hemisphere (figure 1). We also used HR-MRI to rule out vessel stenosis or occlusion due to atherosclerosis, vascular embolism or arteritis. In the enrolled patients, ACA occlusion did not show eccentric stenosis on HR-MRI, and the distal segment of the ICA in the contralateral cerebral hemisphere showed centripetal constriction (online supplemental figure 1). Patients with a diagnosis of moyamoya syndrome or a suspected diagnosis of MMD; life-threatening diseases, such as leukaemia or systemic malignancies; or with poor image quality, incomplete clinical data or inability to undergo MRI examinations were also excluded. The study design flow chart is shown in figure 2.

Sample collection and genotyping

Based on the findings of our previous study and the data from a currently registered cohort study (ChiCTR2200064160),¹¹ we tested the rs112735471 p.R4810K locus of *RNF213* in all enrolled patients who provided informed signed consent. We collected 10 mL peripheral vein blood of recruited patients for assays, and genomic DNA was extracted using a Blood Genetic

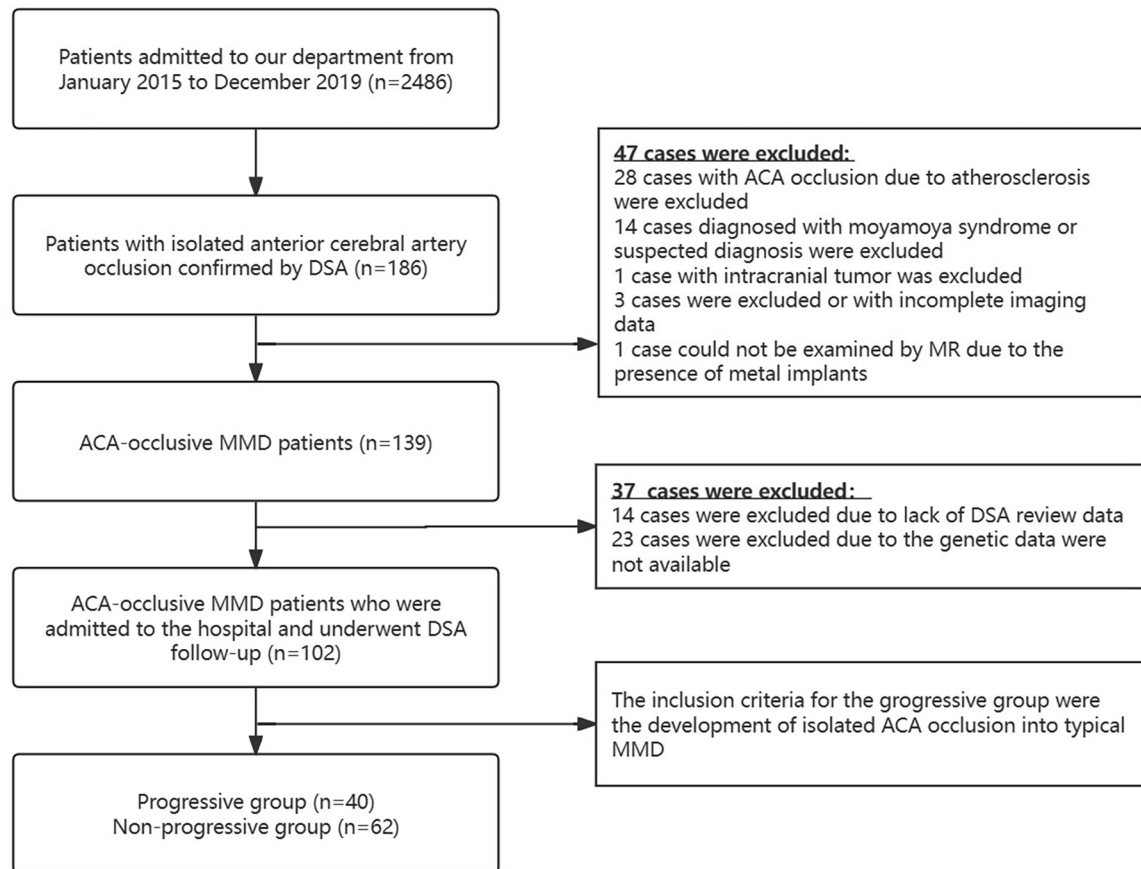


Figure 2 Flow chart of the study.

DNA Mini Kit (CWBIO, Beijing, China). The detail of the method was described in our previous study.¹¹ p.R4810K genotypes were divided into the wild type (genotype GG), the heterozygote (genotype GA), or the mutant homozygote (genotype AA).

Clinical and radiological characteristics

We collected clinical and radiological data per standard protocols during the patients' inaugural visit to our institution. The onset type of ACA-occlusive MMD, defined as an asymptomatic, transient ischaemic attack (TIA), infarction, haemorrhage, headache or other, was based on initial symptoms.

All patients underwent unified standard-based MRI and HR-MRI. ACA-occlusive MMD was categorised based on different cerebral hemispheres into isolated ACA-occluded and contralateral sides. Radiological data included CT, MRI, HR-MRI (negative remodelling, outer diameter of A1 segment of ACA, outer diameter of ipsilateral vertebral artery and remodelling index) and DSA (Suzuki staging, posterior cerebral artery (PCA) involvement) of the isolated ACA-occluded side. Referring to previous studies,^{12 13} the remodelling index of ACA was calculated as $(1 - \text{outer diameter of A1 segment of ACA} / \text{outer diameter of ipsilateral vertebral artery}) \times 100\%$ (online supplemental figure 1). Cerebral infarction on radiology was determined as an infarct lesion with a

maximum diameter ≥ 10 mm on MRI, low signal in the T1 sequence, high signals in the T2 and fluid-attenuated inversion recovery sequences and isosignal or high signal in the diffusion-weighted imaging sequence.¹⁴ Haemorrhage was defined as subarachnoid, intraparenchymal or intraventricular haemorrhage.¹⁵ The diagnosis of intracranial haemorrhage was mainly based on brain imaging (CT or MRI) and the presence of haemorrhage lesions or changes after bleeding.¹⁶

Neuropsychological assessment

A trained cognitive psychologist (HZ) performed all neuropsychological tests. The Montreal Cognitive Assessment (MoCA) was used to assess overall cognitive impairment, with a cut-off of 26 and 1-point correction for persons educated for 12 years.¹⁷ Daily living ability was assessed using the Instrumental Activity of Daily Living Scale (IADL).¹⁸ The 17-item Hamilton Rating Scale for Depression (HAM-D-17) was used to assess depression.¹⁹

Collateral circulation assessment

Collateral compensation in the isolated ACA-occluded hemisphere was gauged using DSA. The assessment comprised two components: leptomeningeal collateral circulation compensation and collateral compensation from the MCA to the ACA. A leptomeningeal collateral circulation grading system with scores from 1 to 12 was

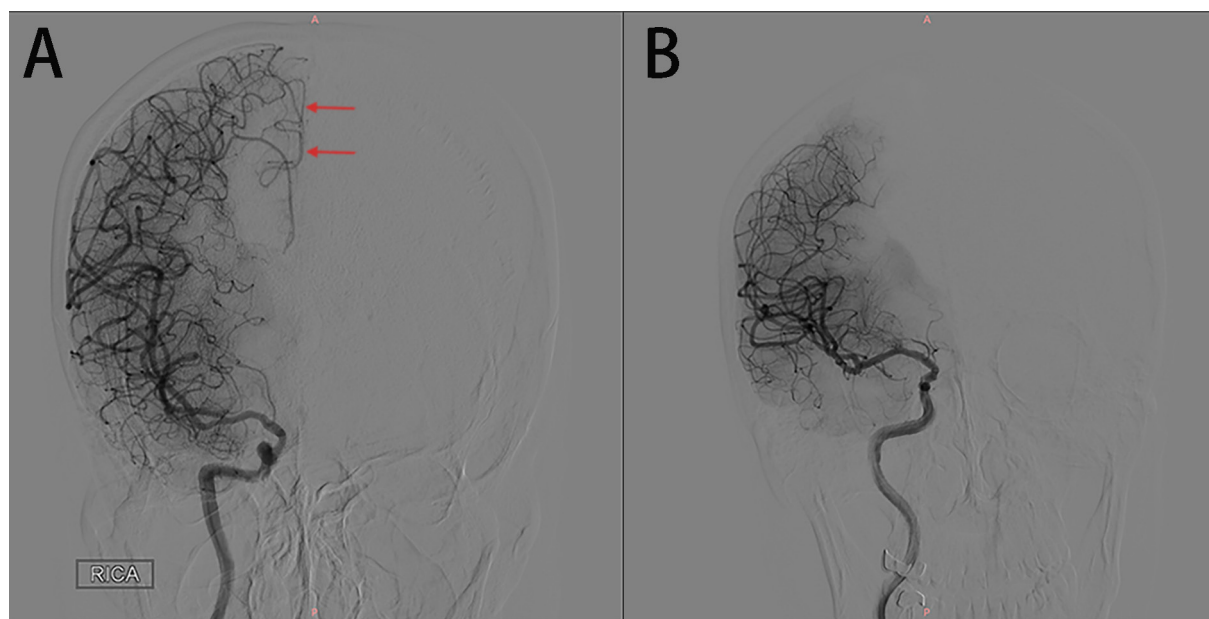


Figure 3 Collateral compensation from the middle cerebral artery (MCA) to the anterior cerebral artery (ACA). (A) As indicated by the arrow, blood flow reaches the medial frontal gyrus through the anastomotic branch of the terminal MCA. (B) Blood flow reaches the ACA territory through the anastomotic branch of the MCA but does not reach the medial frontal gyrus, indicating poor collateral compensation from the MCA to the ACA.

established²⁰: the anatomical extent of pial collateral blood flow from the PCA to the MCA and ACA was scored from 1 to 6. In contrast, perforator collateral and ICA flow received scores from 6 to 1, aligning with Suzuki stages 1–6.

Good compensation from the MCA to the ACA was defined by blood flow reaching the medial frontal gyrus via the terminal MCA's anastomotic branch (figure 3A). Poor compensation was defined as when blood flow reached the ACA territory through the MCA's anastomotic branch without reaching the medial frontal gyrus (figure 3B).

A single interventional neuroradiologist (R-mY) performed DSA on all enrolled patients. Two experienced neurosurgeons (S-ML and GG) analysed and evaluated all radiological data, with the supervising physician resolving any inconsistencies based on the original data.

Clinical follow-up

Follow-up clinical and radiological data were collected. Since the contralateral cerebral hemispheres of the enrolled patients showed typical manifestations of MMD, we performed revascularisation surgery on the contralateral cerebral hemisphere. We recommended that all enrolled patients receive DSA at 6 months to 1 year after surgery to review their disease progression and surgical outcome. In addition, MRI was also reviewed at 6 months, 1 year and annually thereafter to determine the occurrence of ischaemic stroke.

Patients were classified into progression and non-progression groups based on the development of isolated ACA occlusion manifestations into typical MMD (figure 1A,E). We compared the clinical characteristics

between groups and analysed potential factors influencing ACA-occlusive MMD progression. Follow-up stroke was ascertained during clinical visits, defined as the presence of a new infarction in the isolated ACA-occluded hemisphere on MRI.

Statistical analyses

All analyses were executed using SPSS software (V.26.0; IBM, Armonk, New York, USA). We compared continuous variables using the t-test or Wilcoxon signed-rank test and categorical variables via the χ^2 test or Fisher's exact test. Logistic regression was employed to analyse the risk factors for ACA-occlusive MMD progression, while Kaplan-Meier survival analysis was used to compare the incidence of new cerebral infarctions in patients with ACA-occlusive MMD. Statistical significance was inferred when the p value was <0.05.

RESULTS

Clinical and radiological data

The median age at diagnosis of ACA-occlusive MMD was 36 (range, 3–65) years, with 27 patients (19.4%) being less than 18 years old (table 1). The age distribution of ACA-occlusive MMD predominantly showed an adult peak, particularly between 35 and 40 years, preceded by a smaller peak between 25 and 30 years (figure 4). The female-to-male patient ratio was 1.32:1. Among the 139 patients, 41 (29.5%) had hypertension, 14 (10.1%) had diabetes mellitus, 21 (15.1%) had hyperlipidaemia, 22 (15.8%) had hyperhomocysteinaemia, 6 (4.3%) had hyperthyroidism, 7 (5.0%) had coronary heart disease and 7 (5.0%) had a family history of MMD.

Table 1 Characteristics of patients with ACA-occlusive MMD

	Number (n=139)	%
Sex ratio (F/M)	1.32:1 (79:60)	
Median age at diagnosis (range)	36 (3–65)	
Age <18 years old	27	19.4
Vascular risk factors		
Hypertension	41	29.5
Diabetes	14	10.1
Hyperlipidaemia	21	15.1
Hyperhomocysteinaemia	22	15.8
Hyperthyroidism	6	4.3
Coronary heart disease	7	5.0
Family history	7	5.0
Primary symptom at onset		
Asymptomatic	1	0.7
Transient ischaemic attack	87	62.6
Infarction	15	10.8
Haemorrhage	24	17.3
Headache	6	4.3
Others	6	4.3
Initial mRS score >2	5	3.6
Side ratio (right:left)	1.28:1 (78:61)	
PCA involvement	20	14.4
HR-MRI features		
Negative remodelling	122	87.8%
Outer diameter of A1 segment of ACA (mean±SD)	1.50±0.56	
Outer diameter of ipsilateral vertebral artery (mean±SD)	3.14±0.25	
Remodelling index (mean±SD)	0.53±0.16	
Neuropsychological assessment*		
MoCA (mean±SD)	21.82±4.21	
IADL (mean±SD)	14.48±1.89	
HAMD-17 (mean±SD)	4.37±3.80	
Mutation†		
GG	90/116	77.6
GA	26/116	22.4

*The neuropsychological assessment was performed in 116 of the 139 patients.

†*RNF213* p.R4810K (rs112735431) gene mutation analysis was performed in 116 of the 139 patients.

ACA, anterior cerebral artery; GA, heterozygous *RNF213* p.R4810K; GG, wild type *RNF213* p.R4810K; HAMD-17, 17-item Hamilton Rating Scale for Depression; IADL, Instrumental Activity of Daily Living Scale; MMD, moyamoya disease; MoCA, Montreal Cognitive Assessment; mRS, Modified Rankin Scale; PCA, posterior cerebral artery.

The primary symptoms at onset were as follows: 1 patient (0.7%) was asymptomatic, 87 patients (62.6%) experienced a TIA, 15 patients (10.8%) suffered infarction, 24 patients (17.3%) had suffered from haemorrhage, 6 patients (4.3%) experienced headaches and 6 patients (4.3%) presented other symptoms. An initial Modified Rankin Scale (mRS) score >2 was observed in five patients (3.6%). PCA involvement was seen in 20 patients (14.4%). According to *RNF213* p.R4810K (rs112735431) gene mutation analysis, 90 patients (77.6%) had the GG genotype, 26 patients (22.4%) had the GA genotype and none had the AA genotype (table 1). 122 cases (87.8%) showed negative remodelling on HR-MRI, with a mean remodelling index of 0.53±0.16. There were no significant differences in primary symptoms or genotypes between adult and paediatric patients (online supplemental table 1).

Neuropsychological assessment of patients with ACA-occlusive MMD

The neuropsychological test performances of the participants are summarised in table 1, and the specific test score distribution is summarised in online supplemental table 2. Of 139 patients with ACA-occlusive MMD, 65 were evaluated for MoCA, IADL and HAMD-17. The mean MoCA score was 21.82±4.21 in ACA-occlusive MMD; 18 patients (27.7%) had normal MoCA scores (≥26), 37 patients (56.9%) had mild cognitive impairment (MoCA 18–26) and 10 patients (15.4%) had moderate cognitive impairment (MoCA 10–17). The mean IADL score was 14.48±1.89 in ACA-occlusive MMD; 59 patients (90.8%) were completely normal, 5 patients (7.7%) had varying degrees of functional decline and 1 patient (1.5%) had significant functional impairment. The mean HAMD-17 score was 4.37±3.80 in ACA-occlusive MMD; 49 patients (75.4%) were normal and 16 patients (24.6%) had probable depressive symptoms.

Differences between the progression and non-progression group

Of the 102 patients who underwent DSA re-examination, 40 patients (39.2%) progressed from ACA-occlusive MMD to typical MMD. Clinical and radiological characteristic differences between groups were compared (table 2). Patients in the progression group were younger than those in the non-progression group (28.50 (9.00–36.00) vs 37.50 (25.75–45.25), $p<0.001$). Hypertension prevalence was lower in the progression group compared with the non-progression group (15.0% vs 33.9%, $p=0.035$). The rate of good collateral compensation from the MCA to the ACA was lower in the progression group (40.0% vs 74.2%, $p<0.001$). The GA mutation carrier rate in the progression group was significantly higher than that in the non-progression group (35.0% vs 14.5%, $p=0.016$). The outer diameter of A1 segment of ACA (1.39±0.58 vs 1.64±0.64, $p=0.042$) and ipsilateral vertebral artery (3.00±0.30 vs 3.19±0.23, $p=0.002$) in the progression group was smaller than that

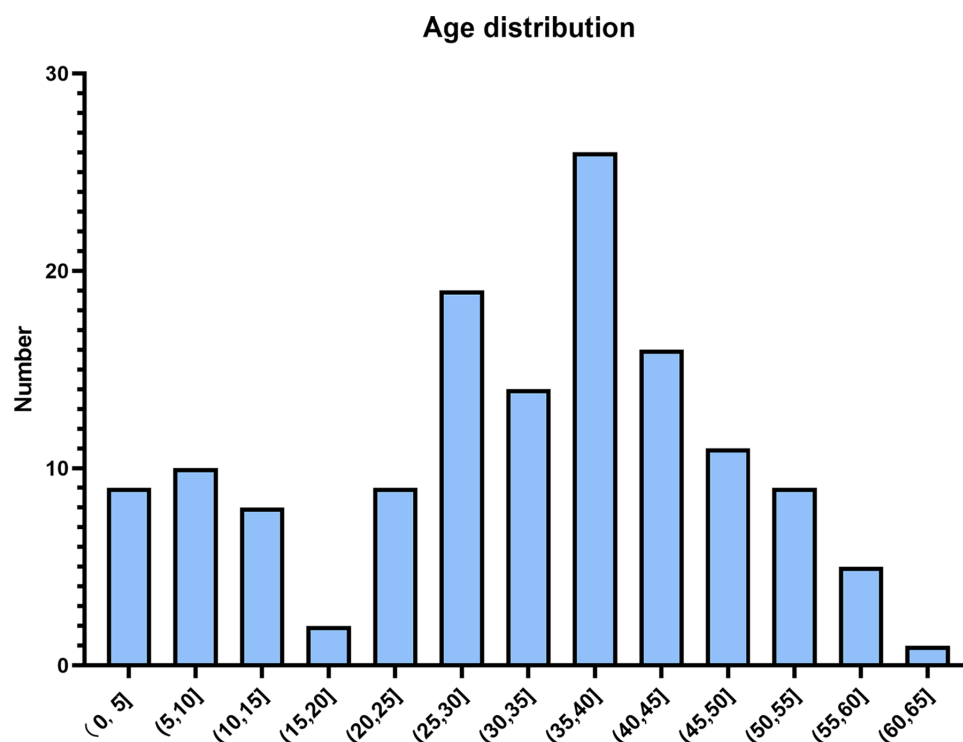


Figure 4 The age distribution of anterior cerebral artery-occlusive moyamoya disease.

in the non-progression group. There was no significant difference in the remodelling index between the two groups ($p=0.148$).

Follow-up outcomes of patients with ACA-occlusive MMD in the progression and non-progression groups

During the median follow-up periods of months 18.50 (IQR, 8.25–25.75) and 18.00 (IQR, 10.75–36.50) months for the progression and non-progression groups, respectively, eight cases (20.0%) of infarction in the progression group and four (6.5%) in the non-progression group were recorded. The annual infarction rates were 11.8% and 3.0% per year for the progression and non-progression groups, respectively. Kaplan-Meier follow-up estimates that a higher incidence of ischaemic stroke is associated with progression (figure 5A, $p=0.035$ for log-rank test).

Risk factors for progression

Multivariate logistic regression analysis showed that age ($p=0.041$; OR 0.965; 95% CI 0.933 to 0.999), GA genotype ($p=0.037$; OR 3.232; 95% CI 1.071 to 9.751) and good collateral compensation from the MCA to the ACA ($p=0.001$; OR 0.466; 95% CI 0.292 to 0.745) were significantly associated with progression (table 3).

The receiver operating characteristic curve demonstrated that younger age, GA genotype and poor collateral compensation from the MCA to the ACA predicted a higher rate of progression, with a sensitivity and specificity of 77.5% and 77.4%, respectively. The area under the curve was 0.799 (95% CI 0.710 to 0.888; $p<0.001$; figure 5B).

DISCUSSION

This retrospective cohort study highlights that patients with ACA-occlusive MMD have similar clinical and radiological features to patients with typical MMD manifestations. Cognitive decline and TIA might be the main manifestations of ACA-occlusive MMD. The median age of patients with ACA-occlusive MMD in the progression group was younger, and age, GA genotype and the extent of compensation from MCA to ACA were associated with this progression. During follow-up, ischaemic stroke developed in 12 cases. Patients with ACA-occlusive MMD who progressed had a higher follow-up stroke rate (20.0%).

At present, the relationship between MMD and isolated ACA occlusion is not clear. During clinical diagnosis, isolated ACA occlusion in at least one cerebral hemisphere occurred in approximately 6.8% of all patients diagnosed with MMD in our department. However, there is little literature on cases with such radiological manifestations. Traditionally, a classic MMD site initially involves the terminal portion of the ICA and gradually involves the proximal portions of the ACA and MCA as the disease progresses. Meanwhile, Kim *et al.*²¹ also suggested that non-atherosclerotic isolated MCA occlusion might be an early manifestation of MMD. However, whether ACA occlusion is an early manifestation of MMD has not been clearly reported in the past. As such, we identified ACA-occlusive MMD as a unique entity and conducted a cohort study to elucidate the relationship between ACA occlusion and MMD.

Table 2 Characteristics of progression and non-progression groups

First admission	Progression (n=40)	Non-progression (n=62)	P value
Female	21 (52.5)	36 (58.1)	0.581
Age at diagnosis (years)			0.001
Median (Q1, Q3)	28.50 (9.00–36.00)	37.50 (25.75–45.25)	
Range	3–44	3–60	
Vascular risk factors			
Hypertension	6 (15.0)	21 (33.9)	0.035
Diabetes	1 (2.5)	8 (12.9)	0.147
Hyperlipidaemia	5 (12.5)	8 (12.9)	0.952
Hyperhomocysteinaemia	6 (15.0)	9 (14.5)	0.946
Hyperthyroidism	2 (5.0)	3 (4.8)	1.000
Coronary heart disease	0	4 (6.5)	0.153
Family history	3 (7.5)	3 (4.8)	0.899
Primary symptom at onset			
Asymptomatic	0	1 (1.6)	1.000
TIA	24 (60.0)	41 (66.1)	0.530
Infarction	6 (15.0)	6 (9.7)	0.415
Haemorrhage	7 (17.5)	12 (19.4)	0.814
Headache	2 (5.0)	1 (1.6)	0.698
Others	1 (2.5)	1 (1.6)	1.000
Initial mRS score >2	0	3 (4.8)	0.278
MCA-ACA			0.001
Good	16 (40.0)	46 (74.2)	
Poor	24 (60.0)	16 (25.8)	
Leptomeningeal collateral assessment	7.73±1.50	7.35±1.88	0.265
PCA involvement	2 (5.0)	9 (14.5)	0.236
HR-MRI features			
Negative remodelling	36 (90.0%)	50 (80.6%)	0.205
Outer diameter of A1 segment of ACA	1.39±0.58	1.64±0.64	0.042
Outer diameter of ipsilateral vertebral artery	3.00±0.30	3.19±0.23	0.002
Remodelling index	0.54±0.17	0.49±0.18	0.148
Mutation			0.016
GG	26 (65.0)	53 (85.5)	
GA	14 (35.0)	9 (14.5)	
Neuropsychological assessment			
MoCA	22.35±4.98	22.03±3.50	0.631
IADL	14.12±0.49	14.41±1.32	0.576
HAMD-17	3.24±2.61	5.69±4.52	0.082
Follow-up			
Follow-up duration (month)			0.223
Median (Q1, Q3)	18.50 (8.25–25.75)	18.00 (10.75–36.50)	
Range	6–58	6–84	
New infarction	8 (20.0)	4 (6.5)	0.079
Progress of PCA	3 (7.5)	5 (8.1)	1.000
Leptomeningeal collateral assessment	6.25±1.57	7.79±1.43	< 0.001

Results are expressed as number (%), mean±SD or median (IQR).

GA, heterozygous *RNF213* p.R4810K; GG, wild type *RNF213* p.R4810K; HAMD-17, 17-item Hamilton Rating Scale for Depression; IADL, Instrumental Activity of Daily Living Scale; MCA-ACA, compensation from the middle cerebral artery to the anterior cerebral artery; MoCA, Montreal Cognitive Assessment; mRS, Modified Rankin Scale; PCA, posterior cerebral artery; TIA, transient ischaemic attack.

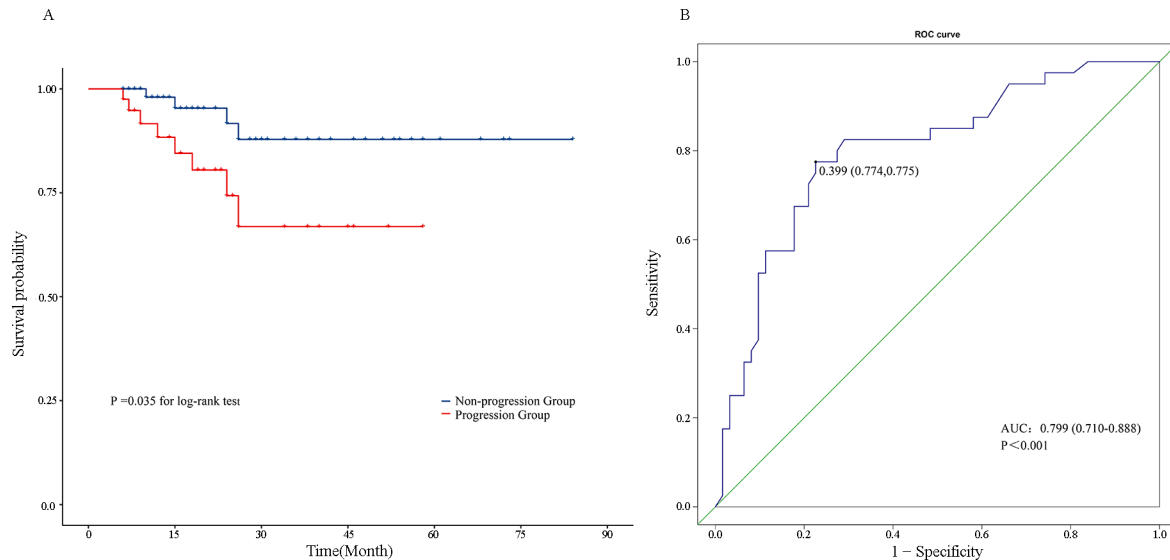


Figure 5 (A) Kaplan-Meier curves for stroke events between the progression and non-progression groups during follow-up. (B) Receiver operating characteristic prediction model of age, genotype and compensation from middle cerebral artery to anterior cerebral artery.

Within our ACA-occlusive MMD cohort, we observed a slight female predominance (ratio 1.32:1), which is consistent with previous epidemiological studies of typical MMD.^{15 22} TIA was the most common symptom at onset. The proportion of TIA (62.6%) as an onset symptom was higher, and the incidence of cerebral infarction (10.8%) was lower than that of typical MMD.^{15 23} Unlike typical MMD, ACA-occlusive MMD has an additional compensatory pathway from the MCA to the ACA, resulting in a lower cerebral infarction rate. PCA involvement was found in 14.4% of patients, considerably lower than that observed in patients with typical MMD (30%–58%).^{24–26}

These features suggest that patients with ACA-occlusive MMD have milder initial symptoms.

No precise age peak was observed in paediatric patients with ACA-occlusive MMD (figure 4). Since the ACA primarily supplies blood to the frontal lobe, ischaemia and hypoxia in this region are primarily associated with cognition, emotion, intelligence and memory.^{27 28} Paediatric patients often struggle to express their discomfort accurately, and early cognitive decline can be difficult to detect. Consequently, some patients are not diagnosed during childhood. Given that MMD is a chronic progressive disease,²⁹ some patients might progress from

Table 3 Logistic regression analysis of progression in isolated ACA-occluded hemisphere

Risk factors	Univariate logistic regression		Multivariate logistic regression	
	OR (95% CI)	P value	OR (95% CI)	P value
Age	0.955 (0.929 to 0.983)	0.002	0.965 (0.933 to 0.999)	0.041
Male	1.253 (0.563 to 2.787)	0.581		
Hypertension	0.345 (0.125 to 0.951)	0.040	0.593 (0.182 to 1.938)	0.388
Diabetes	0.173 (0.021 to 1.441)	0.105		
Hyperlipidaemia	0.964 (0.292 to 3.187)	0.952		
Hyperhomocysteinaemia	1.039 (0.339 to 3.182)	0.946		
Hyperthyroidism	1.035 (0.165 to 6.485)	0.971		
Family history	1.595 (0.306 to 8.322)	0.580		
Involvement of PCA	0.310 (0.063 to 1.517)	0.148		
GA genotype	3.171 (1.214 to 8.281)	0.018	3.232 (1.071 to 9.751)	0.037
Good MCA to ACA	0.482 (0.315 to 0.737)	0.001	0.466 (0.292 to 0.745)	0.001
Negative remodelling	2.160 (0.644 to 7.243)	0.212		
Remodelling index	6.020 (0.519 to 69.853)	0.151		

ACA, anterior cerebral artery; GA, heterozygous *RNF213* p.R4810K; MCA, middle cerebral artery; PCA, posterior cerebral artery.

ACA-occlusive MMD to typical MMD before presenting apparent symptoms. Therefore, the age of onset in children may be earlier than the age of diagnosis. The age distribution of adults diagnosed with ACA-occlusive MMD was younger than that of typical MMD.¹⁵ These results indicate that patients with ACA-occlusive MMD are younger.

RNF213 has been identified as a susceptibility gene and major founder variant for MMD by genome-wide linkage analyses with exome sequencing, association studies and candidate gene analyses.³⁰ Meanwhile, *RNF213* p.R4810K (rs112735431) has been strongly associated with both sporadic and familial MMD.³¹ Therefore, we tested the rs112735471 p.R4810K locus of *RNF213* for all enrolled cases who signed informed consent. There were 90 patients (77.6%) with the GG genotype and 26 patients (22.4%) with the GA genotype in the present study (table 1), which was consistent with previous studies (16.7%–23%) in a Chinese cohort of MMD.^{32–33} There was no significant difference in the *RNF213* p.R4810K (rs112735431) mutation carrier rate between ACA-occlusive and typical MMD, indicating that the founder variant did not significantly affect the clinical progression of MMD. These data suggest that ACA-occlusive and typical MMD have similar genetic backgrounds. From a genetic perspective, ACA-occlusive and typical MMD should be different developmental stages of the same disease.

At the same time, we observed that some patients who initially had proximal ACA lesions without ICA involvement could progress to classic MMD during follow-up. Combining clinical features, genetic background and disease progression, we conclude that isolated ACA occlusion may be an early manifestation of MMD. Based on the results of Kim *et al*,²¹ the initial MMD lesion site is not strictly confined to the terminal portion of the ICA. In some patients with MMD, the initial lesion site could be the proximal sections of the ACA or MCA.

The neuropsychological assessment revealed that 37 patients (56.9%) had mild cognitive impairment and 10 patients (15.4%) had moderate cognitive impairment. According to the IADL scale, 5 patients (7.7%) had varying degrees of functional decline and 1 patient (1.5%) had significant functional impairment. Five patients (3.6%) had mRS scores >2. This suggests that a decline in cognitive function is already present in most patients (72.3%) with ACA-occlusive MMD, but functional impairment is present in only a minority of patients (9.2%). Therefore, cognitive decline and TIA might be the main manifestations of ACA-occlusive MMD. Since isolated ACA occlusion may be an early manifestation of MMD, cognitive decline and TIA may be the main early manifestations in some patients with MMD.

We examined occluded ACAs in all patients using HR-MRI and excluded atherosclerosis and other vascular occlusive diseases. The outer diameter of A1 segment of ACA in the progression group was smaller than that in the non-progression group. Due to the different outer diameters of ACA in patients of different ages, and the

younger and more paediatric patients in the progression group, correction is required. We used the ipsilateral vertebral artery as a reference because MMD usually does not involve the ipsilateral vertebral artery. And the remodelling index showed no difference between the two groups.

Further, we explored which factors contribute to the progression of ACA-occlusive to typical MMD. The progression is more likely to occur at a younger age, aligning with previous observations in patients with typical MMD.^{29–34} The reason younger patients are more likely to progress is not clear but may be related to genetic anticipation and immune responses.

The blood supply from the MCA to the ACA territory via the leptomeningeal collateral branch is unique to ACA-occlusive MMD. According to the three-tier classification method of intracranial collateral circulation proposed by Liebeskind,³⁵ the collateral compensation capacity depends on the calibre, number and patency of the primary pathways. Compared with compensation from the PCA to the MCA or ACA, compensation from the MCA to the ACA appears earlier and has a stronger compensatory ability. Hence, compensation from the MCA to the ACA is the most significant compensatory pathway in isolated ACA occlusion. Typically, the MCA reaches the region of the medial frontal gyrus and pericallosal artery through the terminal anastomosed branch (figure 3A). If blood flow from the MCA cannot reach the medial frontal gyrus region, this signifies altered haemodynamics. Such changes may indicate early shifts in the vascular structure and function, and these patients are more likely to progress.

Previous studies have shown that heterozygous mutation in *RNF213* p.R4810K (rs112735431) is associated with early onset and rapid progression of MMD.³⁶ In our cohort, multivariate regression analysis also showed that the GA genotype is a risk factor for progression. This also demonstrates that *RNF213* p.R4810K (rs112735431) mutation plays an important role in the pathogenesis and rapid progression of patients with ACA-occlusive MMD.

The issue of whether surgical revascularisation should be performed on an isolated ACA-occluded cerebral hemisphere has been a topic of debate. During our follow-up, the annual stroke incidence among our ACA-occlusive MMD cohort was 5.9%, which aligns with previously reported rates for conservatively treated patients with typical MMD (4.5%–19.6%)^{37–38} and exceeds the postrevascularisation treatment ischaemic stroke rate (0.7%–5.2%).^{39–40} Revascularisation can lower the risk of ischaemic stroke in patients with MMD. Meanwhile, patients in the ACA-occlusive MMD progression group displayed a higher annual incidence of cerebral infarction (11.8%). Therefore, early revascularisation treatment may be beneficial for patients with ACA-occlusive MMD with risk factors for progression. Nevertheless, more robust studies are required to validate the necessity for early surgery on the isolated side of ACA occlusion.

Limitations

Our study had several limitations. First, being a single-centre study with a relatively small sample size, selection bias related to region and ethnicity might have been introduced. Second, our exclusion of isolated ACA occlusions due to atherosclerosis, based on HR-MRI findings, was relative rather than absolute. Vascular occlusion could have been a common product of MMD and atherosclerosis for some patients, highlighting the need for further technological advancements to refine the inclusion criteria. Lastly, the potential treatment protocol of ACA-occlusive MMD patients remains to be further explored.

CONCLUSIONS

ACA-occlusive MMD shares similar clinical features and genetic background to typical MMD. Cognitive decline and TIA might be the main manifestations of ACA-occlusive MMD. Isolated ACA occlusion might be an early indicator of MMD and can progress to typical MMD. The initial MMD lesion site is not strictly confined to the terminal portion of the ICA. Younger age, heterozygosity at *RNF213* p.R4810K and poor collateral compensation from the MCA to the ACA are risk factors for the progression of ACA-occlusive MMD to typical MMD.

Acknowledgements We thank the individuals who contributed to the study and manuscript preparation but did not fulfil all the criteria of authorship.

Contributors All authors contributed to the study conception and design. Material preparation, data collection and analysis were performed by M-JW, ZZ, DY, QZ, Q-BG, X-PW, HF, J-JL and S-ML. The patients' DSA was performed by RY. All neuropsychological assessments were performed by HZ. All the radiological data were analysed and evaluated by S-ML and GG and proofread by CH. The measurement and analysis of HR-MRI data were completed by SL and S-ML. The first draft of the manuscript was written by S-ML, FH and LD, and all authors commented on previous versions of the manuscript. CH and LD is the responsible author for this study. All authors read and approved the final manuscript.

Funding This study was supported by grants from the National Natural Science Foundation of China (grant No 82171280 and 82172021).

Competing interests None declared.

Patient consent for publication Consent obtained directly from patient(s).

Ethics approval This retrospective study (KY-2022-9-69-1) was approved by the Ethics Committee of the Fifth Medical Center of the PLA General Hospital and registered with the Chinese Clinical Trial Registry (ChiCTR2200064160). Participants gave informed consent to participate in the study before taking part.

Provenance and peer review Not commissioned; externally peer reviewed.

Data availability statement Data are available upon reasonable request.

Supplemental material This content has been supplied by the author(s). It has not been vetted by BMJ Publishing Group Limited (BMJ) and may not have been peer-reviewed. Any opinions or recommendations discussed are solely those of the author(s) and are not endorsed by BMJ. BMJ disclaims all liability and responsibility arising from any reliance placed on the content. Where the content includes any translated material, BMJ does not warrant the accuracy and reliability of the translations (including but not limited to local regulations, clinical guidelines, terminology, drug names and drug dosages), and is not responsible for any error and/or omissions arising from translation and adaptation or otherwise.

Open access This is an open access article distributed in accordance with the Creative Commons Attribution Non Commercial (CC BY-NC 4.0) license, which permits others to distribute, remix, adapt, build upon this work non-commercially, and license their derivative works on different terms, provided the original work is properly cited, appropriate credit is given, any changes made indicated, and the use is non-commercial. See: <http://creativecommons.org/licenses/by-nc/4.0/>.

ORCID iDs

Xiao-Peng Wang <http://orcid.org/0000-0002-5244-2586>

Cong Han <http://orcid.org/0000-0001-7210-056X>

Lian Duan <http://orcid.org/0000-0001-7210-056X>

REFERENCES

- Thirugnanachandran T, Beare R, Mitchell M, *et al*. Anterior cerebral artery stroke: role of collateral systems on infarct topography. *Stroke* 2021;52:2930–8.
- Gacs G, Fox AJ, Barnett HJ, *et al*. Occurrence and mechanisms of occlusion of the anterior cerebral artery. *Stroke* 1983;14:952–9.
- Kazui S, Sawada T. Callosal apraxia without agraphia. *Ann Neurol* 1993;33:401–3.
- Kang SY, Kim JS. Anterior cerebral artery infarction: stroke mechanism and clinical-imaging study in 100 patients. *Neurology* 2008;70(24 Pt 2):2386–93.
- Arboix A, García-Eroles L, Sellarés N, *et al*. Infarction in the territory of the anterior cerebral artery: clinical study of 51 patients. *BMC Neurol* 2009;9:30.
- Montaser A, Driscoll J, Smith H, *et al*. Long-term clinical and radiographic outcomes after pial pericranial dural revascularization: a hybrid surgical technique for treatment of anterior cerebral territory ischemia in pediatric Moyamoya disease. *J Neurosurg Pediatr* 2021;28:351–9.
- Scott RM, Smith ER. Moyamoya disease and moyamoya syndrome. *N Engl J Med* 2009;360:1226–37.
- Fukui M. “Guidelines for the diagnosis and treatment of spontaneous occlusion of the circle of Willis ('Moyamoya' disease). Research Committee on spontaneous occlusion of the circle of Willis (Moyamoya disease) of the Ministry of health and welfare Japan”. *Clin Neurol Neurosurg* 1997;99 Suppl 2(Suppl 2):S238–40.
- Kuroda S, Fujimura M, Takahashi J, *et al*. Diagnostic criteria for moyamoya disease - 2021 revised version. *Neurol Med Chir(Tokyo)* 2022;62:307–12.
- Cho H, Kim T, Kim Y-D, *et al*. A clinical study of 288 patients with anterior cerebral artery infarction. *J Neurol* 2022;269:2999–3005.
- Wang Y, Zhang Z, Wei L, *et al*. Predictive role of heterozygous P. R4810K of *RNF213* in the phenotype of Chinese moyamoya disease. *Neurology* 2020;94:e678–86.
- Ryoo S, Cha J, Kim SJ, *et al*. High-resolution magnetic resonance wall imaging findings of moyamoya disease. *Stroke* 2014;45:2457–60.
- Cogswell PM, Lants SK, Davis LT, *et al*. Vessel wall and lumen features in North American moyamoya patients. *Clin Neuroradiol* 2020;30:545–52.
- Yu T, Wang R, Ye X, *et al*. Angioarchitectural factors associated with postoperative cerebral infarction in ischemic moyamoya disease. *Brain Sci* 2022;12:10.
- Duan L, Bao XY, Yang WZ, *et al*. Moyamoya disease in China: its clinical features and outcomes. *Stroke* 2012;43:56–60.
- Cao Y, Yu S, Zhang Q, *et al*. Chinese stroke association guidelines for clinical management of cerebrovascular disorders: executive summary and 2019 update of clinical management of intracerebral haemorrhage. *Stroke Vasc Neurol* 2020;5:396–402.
- Kasten M, Bruggemann N, Schmidt A, *et al*. Validity of the MoCA and MMSE in the detection of MCI and dementia in parkinson disease. *Neurology* 2010;75:478;
- Lahav O, Katz N. Independent older adult's IADL and executive function according to cognitive performance. *OTJR (Thorofare N J)* 2020;40:183–9.
- HAMILTON M. A rating scale for depression. *J Neurol Neurosurg Psychiatry* 1960;23:56–62.
- Liu ZW, Han C, Zhao F, *et al*. Collateral circulation in moyamoya disease: a new grading system. *Stroke* 2019;50:2708–15.
- Kim YJ, Lee JK, Ahn SH, *et al*. Nonatherosclerotic isolated middle cerebral artery disease may be early manifestation of moyamoya disease. *Stroke* 2016;47:2229–35.
- Baba T, Houkin K, Kuroda S. Novel epidemiological features of moyamoya disease. *J Neurol Neurosurg Psychiatry* 2008;79:900–4.
- Liu X, Zhang D, Wang S, *et al*. Clinical features and long-term outcomes of moyamoya disease: a single-center experience with 528 cases in China. *J Neurosurg* 2015;122:392–9.
- Yamada I, Himeno Y, Suzuki S, *et al*. Posterior circulation in moyamoya disease: angiographic study. *Radiology* 1995;197:239–46.
- Funaki T, Takahashi JC, Takagi Y, *et al*. Impact of posterior cerebral artery involvement on long-term clinical and social outcome of pediatric moyamoya disease. *J Neurosurg Pediatr* 2013;12:626–32.
- Hishikawa T, Tokunaga K, Sugiu K, *et al*. Assessment of the difference in posterior circulation involvement between pediatric and adult patients with moyamoya disease. *J Neurosurg* 2013;119:961–5.

- 27 Miller EK, Cohen JD. An integrative theory of prefrontal cortex function. *Annu Rev Neurosci* 2001;24:167–202.
- 28 Buschman TJ, Miller EK. Top-down versus bottom-up control of attention in the prefrontal and posterior parietal cortices. *Science* 2007;315:1860–2.
- 29 Piao J, Wu W, Yang Z, et al. Research progress of moyamoya disease in children. *Int J Med Sci* 2015;12:566–75.
- 30 Ihara M, Yamamoto Y, Hattori Y, et al. Moyamoya disease: diagnosis and interventions. *Lancet Neurol* 2022;21:747–58.
- 31 Koizumi A, Kobayashi H, Hitomi T, et al. A new horizon of moyamoya disease and associated health risks explored through RNF213. *Environ Health Prev Med* 2016;21:55–70.
- 32 Zhu B, Liu X, Zhen X, et al. RNF213 gene polymorphism rs9916351 and rs8074015 significantly associated with moyamoya disease in Chinese population. *Ann Transl Med* 2020;8.
- 33 Duan L, Wei L, Tian Y, et al. Novel susceptibility loci for moyamoya disease revealed by a genome-wide association study. *Stroke* 2018;49:11–8.
- 34 Yeon JY, Shin HJ, Kong DS, et al. The prediction of contralateral progression in children and adolescents with unilateral moyamoya disease. *Stroke* 2011;42:2973–6.
- 35 Liebeskind DS. Collateral circulation. *Stroke* 2003;34:2279–84.
- 36 Miyatake S, Miyake N, Touho H, et al. Homozygous C.14576G>A variant of RNF213 predicts early-onset and severe form of moyamoya disease. *Neurology* 2012;78:803–10.
- 37 Cho WS, Chung YS, Kim JE, et al. The natural clinical course of hemodynamically stable adult moyamoya disease. *J Neurosurg* 2015;122:82–9.
- 38 Noh HJ, Kim SJ, Kim JS, et al. Long term outcome and predictors of ischemic stroke recurrence in adult moyamoya disease. *J Neurol Sci* 2015;359:381–8.
- 39 Bao X-Y, Zhang Y, Wang Q-N, et al. Long-term outcomes after encephaloduroarteriosynangiosis in adult patients with moyamoya disease presenting with ischemia. *World Neurosurg* 2018;115:e482–9.
- 40 Kazumata K, Ito M, Tokairin K, et al. The frequency of postoperative stroke in moyamoya disease following combined Revascularization: a single-university series and systematic review. *J Neurosurg* 2014;121:432–40.