


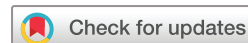Multiple hypointense vessels on susceptibility-weighted imaging predict early neurological deterioration in acute ischaemic stroke patients with severe intracranial large artery stenosis or occlusion receiving intravenous thrombolysis

Yong-Lin Liu ¹, Han-Peng Yin,¹ Dong-Hai Qiu,¹ Jian-Feng Qu,¹ Huo-Hua Zhong ¹, Zhi-Hao Lu,¹ Fang Wang,² Man-Qiu Liang,² Yang-Kun Chen ¹

To cite: Liu Y-L, Yin H-P, Qiu D-H, *et al.* Multiple hypointense vessels on susceptibility-weighted imaging predict early neurological deterioration in acute ischaemic stroke patients with severe intracranial large artery stenosis or occlusion receiving intravenous thrombolysis. *Stroke & Vascular Neurology* 2020;0. doi:10.1136/svn-2020-000343

► Additional material is published online only. To view please visit the journal online (<http://dx.doi.org/10.1136/svn-2020-000343>).

Received 9 February 2020
Revised 13 May 2020
Accepted 30 May 2020



© Author(s) (or their employer(s)) 2020. Re-use permitted under CC BY-NC. No commercial re-use. See rights and permissions. Published by BMJ.

¹Department of Neurology, Dongguan People's Hospital, Dongguan, Guangdong, China
²Department of Radiology, Dongguan People's Hospital, Dongguan, Guangdong, China

Correspondence to
Dr Yang-Kun Chen;
cykun78@163.com

ABSTRACT

Background and purpose Early neurological deterioration (END) is a common feature in patients with acute ischaemic stroke (AIS) receiving thrombolysis. This study aimed to investigate whether the presence of multiple hypointense vessels (MHVs) on susceptibility-weighted imaging (SWI) could predict END in patients with the anterior circulation AIS treated with recombinant tissue plasminogen activator (r-tPA).

Methods This was a retrospective study focusing on AIS patients suffering from symptomatic stenosis or occlusion of the middle cerebral artery or internal carotid artery with r-tPA treatment. We collected clinical variables and initial haematological and neuroimaging findings. MHVs were measured on SWI performed after intravenous thrombolysis and were defined as the presence of a greater number of veins or vessels of a larger diameter with greater signal loss on SWI than those of the contralateral hemisphere. The degree of hyperintensity of MHVs was classified into four grades: none, subtle, moderate and extensive. END was defined as an increase in the National Institutes of Health Stroke Scale score by 2 points during the first 48 hours after the onset of symptoms. Multivariate logistic regressions were conducted to investigate the predictors of END.

Results The study included 61 patients (51 males and 10 females) with a mean age of 62.4±12.6 years. Thirty-five (57.4%) patients presented with MHVs: 8 (13.1%) were graded as subtle MHVs, while 23 (37.7%) and 4 (6.6%) were graded as moderate or extensive MHVs, respectively. Twenty patients (32.8%) presented with END. Logistic regression analysis showed that compared with patients without MHVs, moderate MHVs (adjusted OR 5.446, 95% CI 1.360 to 21.800; p=0.017) and extensive MHVs (adjusted OR 15.240, 95% CI 1.200 to 193.544; p=0.036) were significantly associated with END.

Conclusions MHVs might be a useful predictor of END in AIS patients with symptomatic large artery stenosis or occlusion after r-tPA treatment.

INTRODUCTION

Early neurological deterioration (END) has been reported to be related to a poor outcome and occurs commonly in patients suffering from acute ischaemic stroke (AIS).¹ According to the literature, the incidence of END in AIS patients varies from 16.3% to 37.5%.^{2–5} Some biomarkers of END are identified in recent years, including the fibrinogen level,³ hyperglycaemia,⁶ homocysteine,⁷ serum triglyceride⁸ and D-dimer levels.⁹ In addition, several imaging markers are associated with END, including computed tomographic signs of cerebral oedema,⁵ lacunar strokes¹⁰ and severe large artery stenosis and occlusion.² Other studies have demonstrated that large vessel disease^{11–12} and a lack of recanalisation¹³ are good predictors for the occurrence of END after intravenous thrombolysis (IVT).

Susceptibility-weighted imaging (SWI) is a MRI sequence that is highly sensitive to paramagnetic materials, including deoxyhaemoglobin and haemosiderin.^{14–15} The cerebral veins can be seen more prominently on SWI as multiple hypointense vessels (MHVs) in acute ischaemic cerebral haemispheres.^{16–17} A previous study indicated that the presence of MHVs was a novel marker for predicting END in AIS patients.¹⁸ However, not all patients in this earlier study were suffering from severe intracranial large artery stenosis or occlusion (ILASO), which are factors highly correlated with both MHVs and END.¹⁹ Previous studies have found that the presence of MHVs was related to a poor outcome in AIS patients

with ILASO, which suggested that MHVs might be predictive of outcomes in patients with ILASO.^{20 21} A growing body of evidence currently suggests that the perfusion status of ischaemic brain regions is also associated with END in AIS patients^{11 22 23}; furthermore, SWI can detect the regional perfusion status in an efficient but indirect manner.¹⁶ Thus, we hypothesised that the presence of MHVs could also be a useful predictive marker for END in such patients.

However, to our knowledge, a few studies have investigated the specific relationship between the presence of MHVs and END in patients with anterior circulation AIS treated with IVT. Therefore, we aimed to evaluate the effects of MHVs on END in patients with AIS in the anterior circulation suffering from stenosis or occlusion of the symptomatic middle cerebral artery (MCA) or internal carotid artery (ICA) following IVT therapy.

METHODS

Patients

We prospectively recruited AIS patients who received recombinant tissue plasminogen activator (r-tPA) IVT therapy in Dongguan People's Hospital between 1 January 2016 and 31 October 2019. We then retrospectively analysed data from all subjects receiving thrombolysis. The inclusion criteria were as follows: (1) age >18 years, (2) treatment with r-tPA within 4.5 hours of onset of stroke symptoms, (3) prestroke modified Rankin Scale score ≤1 and (4) symptomatic severe ILASO or occlusion confirmed by MR angiography (MRA). Patients were excluded according to the following criteria: (1) MRI-confirmed AIS of the posterior circulation, (2) parenchymatous haemorrhage (PH) evident on CT following END, (3) lack of SWI data, (4) severe ILASO contralateral to the infarction and (5) direct thrombectomy or thrombectomy following IVT.

Because visual comparison of the severity of signal loss between haemispheres is essential during MHVs assessment, it follows that severely compromised contralateral haemodynamics could, in theory, render vessel signs less obvious. Therefore, we excluded subjects with severe contralateral ICA/MCA stenosis or occlusion. In

addition, because it is difficult to assess MHVs on SWI in patients with haematoma within the infarction, we also excluded patients with PH transformation.

All subjects provided informed consent in accordance with the Declaration of Helsinki.

Clinical data collection

We acquired clinical data from each patient, including the National Institutes of Health Stroke Scale (NIHSS) score, onset to treatment time (OTT), demographic data including age, sex, history of hypertension, diabetes mellitus, smoking, atrial fibrillation, and previous stroke, and initial haematological findings including the homocysteine level, blood glucose (BG) level on admission and neutrophil to lymphocyte ratio.

Clinical outcomes

END was defined as an increase in the NIHSS score by 2 points²⁴ during the first 48 hours after the onset of symptoms. A second CT scan was performed when END occurred to confirm whether PH was evident.

Imaging analysis

Brain MRI following IVT was performed within 72 hours of the onset of stroke for each patient, including T1-weighted imaging, T2-weighted imaging, fluid-attenuated inversion recovery, diffusion weighted imaging (DWI), SWI and three-dimensional time-of-flight MRA (3D-TOF-MRA). All scanning was carried out with a 3.0 T system (Skyra, Siemens Medical, Erlangen, Germany). The parameters for each sequence are shown in [table 1](#).

MHVs were measured on SWI scans performed following IVT and were defined as a greater number of veins or larger veins with greater signal loss on SWI than those of the contralateral haemisphere.²⁵ According to a previous study,²⁵ MHVs were classified into four grades, based on the number of defined areas occupied (according to the Alberta Stroke Programme Early CT (ASPECT) score.²⁶ The defined areas were as follows: 'Ins', 'M1', 'M2', 'M3', 'M4', 'M5', 'M6' and 'Deep'. The criteria used for the classification of the MHV grade were as follows: (1) 'none', no MHVs in any MCA territory; (2) 'subtle', MHVs in 1–3 defined areas of the MCA territory;

Table 1 The parameters for each sequence of MRI scan

	TR (ms)	TE (ms)	FOV (mm ² /mm ³)	ST/gap (mm)	TA (s)	ETL	ESP (ms)	Slice no	Scanning time (s)
T1WI	1500	11	220×185	4/1.2	86	27	11	25	86
T2WI	4720	96	220×199	4/1.2	110	11	12	25	110
FLAIR	9000	84	230×187	5/1.5	110	5	10.5	25	110
DWI	4640	67	230×218	4/1.2	104	–	–	25	104
SWI	27	20	240×195	3/0.6	88	–	–	Volume scan	143
3D-TOF-MRA	21	3.42	200×160×160	0.7/–0.14	216	–	–	Volume scan	216

3D-TOF-MRA, three-dimensional time-of-flight MR angiography; DWI, diffusion-weighted imaging; ESP, echo spacing; ETL, echo train length; FLAIR, fluid-attenuated inversion recovery; FOV, field of view; ST, slice thickness; SWI, Susceptibility-weighted imaging; TA, time of acquisition; TE, time of echo; TR, time of repetition; T1WI, T1-weighted imaging; T2WI, T2-weighted imaging.

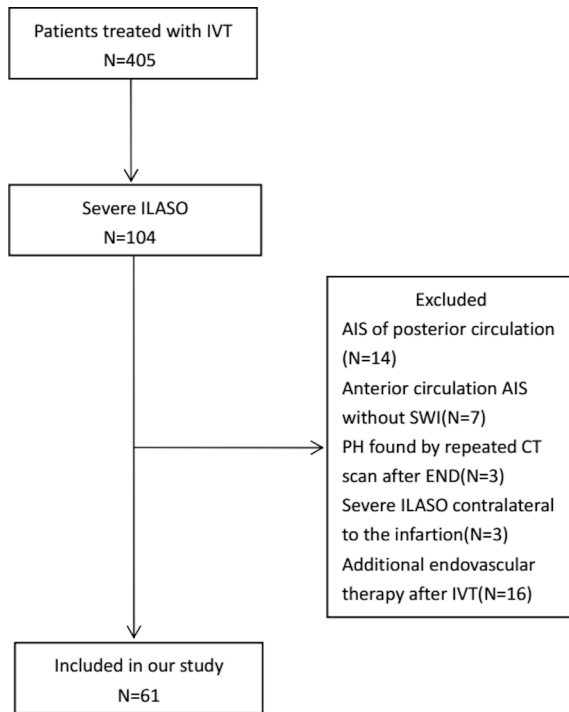


Figure 1 Flow chart of the process used to select subjects. AIS, acute ischaemic stroke; END, early neurological deterioration; ILASO, intracranial large artery stenosis or occlusion; IVT, intravenous thrombolysis; SWI, susceptibility-weighted imaging; PH, parenchymatous haemorrhage.

(3) ‘moderate’, MHVs in 4–6 defined areas of the MCA territory; or (4) ‘extensive’, MHVs in 7–8 defined areas of the MCA territory. A figure demonstrating the assessment of MHV grades is included in the supplemental materials (online supplementary figure S1).

ILASO was evaluated by 3D-TOF-MRA. Symptomatic severe ILASO was defined as cases involving the ICA or M1 segment of the MCA ipsilateral to the infarction with a diameter loss >70%. Symptomatic intracranial large artery occlusion (ILAO) was defined as signal loss of distal blood flow ipsilateral to the infarction. Intracranial stenosis or occlusion was assessed using the Warfarin Aspirin Symptomatic Intracranial Disease criteria.²⁷ PH was assessed according to The European Cooperative Acute Stroke Study II criteria²⁸ by repeated CT scans performed after END onset. The DWI-ASPECT score²⁹ and small vessel disease (SVD) score³⁰ (based on T2-weighted imaging and SWI) were also measured. CT angiography (CTA) or digital subtraction angiography (DSA) were not conducted regularly and were performed depending on the decision of the attending physician.

Two experienced neuroradiologists specialised in MRI (M-QL, an associate consultant with 15 years of experience in neuroradiology; FW, with 10 years of experience in neuroradiology), who were blinded to the clinical information of patients, independently evaluated the imaging findings for each subject, including PH, the DWI-ASPECT and SVD scores, and the severity of ILASO and MHVs. The two observers reviewed and discussed the

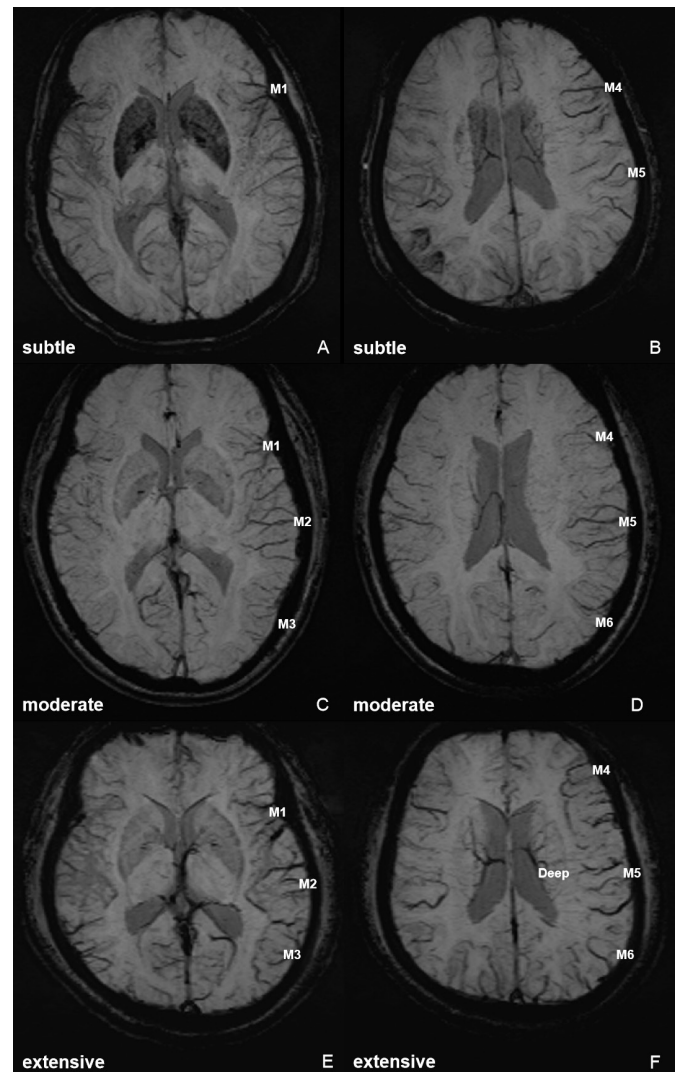


Figure 2 (1) The case of a 74-year-old woman who suffered from AIS for 2 hours. In the left haemisphere, MHVs in M1 (A), M4 and M5 (B) were evident on SWI, and defined as subtle MHVs. (2) The case of a 68-year-old woman who suffered from AIS for 3 hours. In the left haemisphere, MHVs in M1, M2, M3 (C) and M4, M5, M6 (D) were evident on SWI, and defined as moderate MHVs. (3) The case of a 42-year-old man who suffered from AIS for 2 hours. In the left haemisphere, MHVs in M1, M2, M3 (E) and M4, M5, M6, Deep (F) were evident on SWI, and defined as extensive MHVs. AIS, acute ischaemic stroke; Deep, deep white matter; MHVs, multiple hypointense vessels; M1, anterior MCA cortex; M2, MCA cortex lateral to the insular cortex; M3, posterior MCA cortex; M4, M5, M6, the anterior, lateral and posterior MCA territories immediately superior to M1, M2 and M3; MCA, middle cerebral artery; SWI, susceptibility-weighted imaging.

cases for which agreement was not reached, and the final decisions were made by M-QL.

Statistical analysis

Statistical analyses were conducted using SPSS for Windows (V.20.0, IBM). Continuous variables with a normal distribution are reported as means (with SD),

Table 2 Demographic and clinical characteristics of the study cohort

Characteristics	Mean(SD)/median (IQR)/n (%) n=61
Age (years)*	62.4±12.6
Men (n, %)	51 (83.6)
Hypertension (n, %)	37 (60.7)
Diabetes mellitus (n, %)	15 (24.6)
Smokers/ex-smokers (n, %)	28 (45.9)
Atrial fibrillation (n, %)	15 (24.6)
Previous stroke (n, %)	11 (18.0)
OTT (minutes)*	203.5±54.1
NIHSS score on admission†	9 (5–14)
SBP on admission (mm Hg)*	150.6±22.8
DBP on admission (mm Hg)*	89.3±16.9
NLR†	2.4 (1.7–5.9)
BG level on admission(mmol/L)*	7.0±2.3
Homocysteine (mmol/L)*	14.4±6.9
END (n, %)	20 (32.8)
Severe MCA stenosis (n, %)	31 (50.8)
MCA occlusion (n, %)	17 (27.9)
Severe ICA stenosis (n, %)	4 (6.5)
ICA occlusion (n, %)	9 (14.8)
DWI-ASPECT score†	7 (5–8)
MHVs (n, %)	35 (57.4)
Subtle (n, %)	8 (13.1)
Moderate (n, %)	23 (37.7)
Extensive (n, %)	4 (6.6)
SVD burden†	0 (0–1)

*Mean±SD.

†Median (IQR).

ASPECT, Alberta Stroke Programme Early CT ; BG, blood glucose; DBP, diastolic blood pressure; DWI, diffusion-weighted imaging; END, early neurological deterioration; ICA, internal carotid artery; MCA, middle cerebral artery; MHVs, multiple hypointense vessels; NIHSS, National Institutes of Health Stroke Scale; NLR, neutrophil to lymphocyte ratio; OTT, onset to treatment time; SBP, systolic blood pressure; SVD, small vessel disease.

while non-normally distributed variables are reported as the median and IQR. Judgements of the inter-rater and intrarater agreements of measurement of MHVs were made based on Kappa test.

All subjects were divided into two groups with regard to END. Variables were compared between the groups using t-tests, Mann-Whitney U tests, Pearson χ^2 tests or Fisher's exact tests, as appropriate. Variables for which $p \leq 0.1$ in the univariate analysis were subsequently included in further binary multivariate logistic regressions. Statistical significance was defined as $p < 0.05$ (two sided).

RESULTS

During the study period, 405 consecutive patients were treated with r-tPA IVT within 4.5 hours of the onset of stroke. Of these 405 patients, 104 were diagnosed with severe ILASO by MRA. Of these 104 patients, 43 were excluded because of AIS of the posterior circulation (n=14), AIS of the anterior circulation with no SWI data (n=7), detection of PH by repeat CT scanning following END (n=3), severe ILASO contralateral to the infarction (n=3) and additional endovascular therapy after IVT (n=16). Therefore, 61 patients with a mean age of 62.4±12.6 years were included in our final analysis. Twenty-three patients underwent CTA examinations, and two patients underwent DSA examinations. There were no significant differences between the included and excluded patients in terms of age (62.4±12.6 years vs 61.3±12.4 years, $p=0.665$), sex (male, 51 (83.6%) vs 31 (72.1%), $p=0.157$), NIHSS score on admission (median (25–75 IQR), 9 (5–14) vs 8 [6–13], $p=0.979$) or OTT (203.5±54.1 min vs 189.8±58.5 min, $p=0.221$).

A comparison between patients with ILAS and those with ILAO indicated no significant differences in terms of age (63.5±11.6 vs 60.9±14.0 years, $p=0.433$), sex (male, 28 (80.0%) vs 22 (84.6%), $p=0.745$), and NIHSS score on admission (median (25–75 IQR), 9.0 (5.0–15.0) vs 10.5 (5.8–17.3), $p=0.971$); patients with ILAO had more severe MHVs than those with ILAS (from none to extensive, 7 patients (26.9%), 4 patients (15.4%), 12 patients (46.2%) and three patients (11.5%), respectively, vs 19 patients (54.3%), 4 patients (11.4%), 11 patients (31.4%) and one patient (2.9%), p for trend=0.027); patients with ILAO were also more likely to have END (13 patients [50%] vs 7 patients (20%), $p=0.014$). During the study period, 24 patients with large artery occlusion were treated by direct thrombectomy; these patients had a mean age of 66.3±10.3 years and a median NIHSS score on admission of 13 (11–17.75); 16 of these patients (66.7%) were male. A flow chart of the selection process is shown in [figure 1](#).

The median interval between stroke onset and MRI scanning was 42 hours (range, 13–65 hours). Thirty-five patients (57.4%) had severe ILAS (31 patients (50.8%) involving the MCA and 4 patients (6.5%) involving the ICA) and 26 patients (42.6%) had ILAO (17 (27.9%) involving the MCA and 9 (14.8%) involving the ICA). Thirty-five (57.4%) patients presented with MHVs (with grades classified as being \geq subtle) on SWI including 8 (13.1%) graded as subtle, 23 (37.7%) graded as moderate and 4 (6.6%) graded as extensive. The measurement agreement of MHVs was judged to be good (inter-rater kappa value: 0.81; intrarater kappa value: 0.85). Twenty (32.8%) patients presented with END. Three typical cases of MHVs, graded as subtle, moderate and extensive, are shown in [figure 2](#). The demographic and clinical characteristics of this study sample are shown in [table 2](#).

Univariate analysis

Compared with those without END, patients who presented with END had significantly higher BG levels (7.3±2.7 vs

Table 3 Risk factors of END determined by univariable analysis

Variable	END		P value
	With (n=20)	Without (n=41)	
Age* (year)	63.0 (11.1)	62.2 (13.4)	0.818
Men† (n, %)	18 (90.0)	33 (80.5)	0.346
Hypertension† (n, %)	15 (75.0)	22 (53.7)	0.109
Diabetes† (n, %)	6 (30.0)	9 (22.0)	0.493
Smokers/ex-smokers† (n, %)	10 (50.0)	18 (43.9)	0.654
Atrial fibrillation‡ (n, %)	5 (25.0)	10 (24.4)	1.000
Previous stroke† (n, %)	5 (25.0)	6 (14.6)	0.323
OTT* (minutes)	221.6 (46.8)	194.7 (55.9)	0.048
NIHSS score on admission§	7.5 (5–11)	10 (5.5–15.5)	0.100
SBP on admission* (mm Hg)	151.8 (19.5)	150.0 (24.5)	0.769
DBP on admission* (mm Hg)	92.6 (17.4)	87.7 (16.7)	0.301
NLR§	2.7 (1.7–7.5)	2.4 (1.7–4.5)	0.484
BG on admission* (mmol/L)	7.3 (2.7)	6.3 (1.1)	0.041
Homocysteine* (mmol/L)	15.7 (9.1)	13.8 (5.5)	0.305
DWI-ASPECT score§	6.0 (5.0–7.5)	7.0 (5.5–8.0)	0.211
MHV† (n, %)			0.003
None	4 (20.0)	22 (53.7)	
Subtle	2 (10.0)	6 (14.6)	
Moderate	11 (55.0)	12 (29.3)	
Extensive‡	3 (15.0)	1 (2.4)	
SVD‡	0 (0–1)	0 (0–2)	0.747

*Mean (SD), t-test.

†n(%), χ^2 test.

‡Fisher's exact test.

§Median (IQR), Mann-Whitney U test.

ASPECT, Alberta Stroke Programme Early CT Score; BG, blood glucose; DBP, diastolic blood pressure; DWI, diffusion-weighted imaging; END, early neurological deterioration; MHVs, multiple hypointense vessels; NIHSS, National Institutes of Health Stroke Scale; NLR, neutrophil to lymphocyte ratio; OTT, onset to treatment time; SBP, systolic blood pressure; SVD, small vessel burden.

6.3±1.1, $p=0.041$, crude OR 0.759), a significantly longer OTT (221.6±46.8 vs 194.7±55.9, $p=0.048$, crude OR=1.010), and significantly more severe MHVs (moderate, 11 (55.0%) vs 12 (29.3%), crude OR=5.042; extensive, 3 (15.0%) vs 1 (2.4%), crude OR=16.500) ($p=0.003$). The results derived from comparisons between patients with and without END are shown in table 3.

Multivariate logistic regression

Variables identified to show significant differences between the two groups ($p\leq 0.1$) in the univariable analysis, including the OTT, NIHSS score on admission, BG level on admission and MHVs as well as age and sex were subsequently entered into logistic regression models. The analysis showed that compared with patients without

MHVs, moderate MHVs (adjusted OR=5.446; 95% CI 1.360 to 21.800; $p=0.017$) and extensive MHVs (adjusted OR 15.240; 95% CI 1.200 to 193.544, $p=0.036$) were significantly associated with END, while subtle MHVs were not associated with END ($p=0.468$). The multivariate logistic regression analyses are shown in table 4.

DISCUSSION

In the present study, we identified that the presence of MHVs was associated with END in patients with anterior circulation AIS receiving IVT therapy. Both moderate and extensive grades of MHVs were able to predict END (OR 5.446 and OR 15.240, respectively). As SWI is increasingly being applied for patients with AIS, this finding may help physicians to identify those at a relatively high risk of END.

MHVs have been hypothesised to be related to increased deoxyhaemoglobin^{15 31} because of the reduced oxygen saturation in hypointense vessels.³² An increased oxygen extraction fraction in ischaemic tissue with a large perfusion–diffusion mismatch (PDM) leads to an increased deoxyhaemoglobin–oxyhaemoglobin ratio, which results in more prominent MHVs on SWI.²⁵ According to several previous studies, the presence of MHVs might also reflect poor perfusion within the infarction territory^{16 18 33 34}; poor levels of perfusion have also been correlated with the occurrence of END in AIS patients.^{11 22 23} Consequently, there appears to be a correlation between the presence of MHVs and END. A larger PDM has been reported to be related to END,^{11 23 35} and more severe MHVs were associated with larger PDM.²⁵ Therefore, this could explain why moderate and extensive MHVs were related to END while subtle MHVs were not associated with END. This finding indicated that the correlation between the presence of MHVs and END was non-linear, and a threshold might exist when using MHVs to predict END.

The presence of MHVs was highly correlated with prominent ILASO.¹⁹ However, in our study, 26 (42.6%) patients had prominent ILASO but lacked MHVs. We hypothesise that this phenomenon is related to the collateral circulation. Indeed, a previous study also reported that the presence of MHVs was related to poor collateral circulation.³⁶ Therefore, the patients in our study who did not have MHVs might have had relatively good collateral circulation.

In our study, we evaluated intracranial arteries by 3D-TOF-MRA, which increased the difficulty of completely distinguishing ILAO from ILAS. Meanwhile, MHVs could present in patients with either ILAS or ILAO, and ILASO was examined as a whole in a previous study.²⁰ Therefore, it would be reasonable to combine ILAS and ILAO into the category of ILASO.

There were several advantages to our study. First, this is one of only a few studies that have focused on the specific relationship between the presence of MHVs and END after IVT. In addition, we used a semiquantitative method of assessment to evaluate the predictive value of MHVs. However, there were also several limitations to our study

Table 4 The identification of predictors for END by multivariate logistic regression

Variable	END			
	Crude OR (95% CI)	Unadjusted p value	Adjusted OR (95% CI)	Adjusted p value
Age	1.005 (0.963 to 1.049)	0.814	1.031 (0.973 to 1.093)	0.306
Sex	0.395 (0.077 to 2.031)	0.266	0.303 (0.042 to 2.194)	0.237
OTT	1.010 (0.999 to 1.021)	0.073	1.011 (0.998 to 1.023)	0.090
NIHSS	0.902 (0.805 to 1.010)	0.073	0.913 (0.805 to 1.035)	0.154
BG on admission	0.759 (0.531 to 1.084)	0.129	1.012 (0.999 to 1.026)	0.067
MHVs	–	0.043	–	0.049
None (as reference)	–	–	–	–
Subtle	1.833 (0.268 to 12.536)	0.537	2.083 (0.287 to 15.111)	0.468
Moderate	5.042 (1.316 to 19.317)	0.018	5.446 (1.360 to 21.800)	0.017
Extensive	16.500 (1.353 to 201.290)	0.028	15.240 (1.200 to 193.544)	0.036

BG, blood glucose; END, early neurological deterioration; MHVs, Multiple hypointense vessels; NIHSS, National Institutes of Health Stroke Scale; OTT, onset to treatment time.

that need to be considered. First, the sample size was relatively small, and only four patients (6.6%) in our study had extensive MHVs, which may lead to a limitation of the statistical power. Second, because MHVs were only assessed once, it was not possible to examine dynamic changes. Third, CTA or DSA was performed for only a few of our patients, potentially resulting in an overestimation of intracranial stenosis and uncertainty regarding recanalisation of the occluded vessels and the collateral circulation to the infarction. Finally, in our study, the median interval between stroke onset and MRI scanning was 42 hours (range, 13–65 hours), which meant that END may have occurred prior to MRI scanning in some cases. This might partially reduce the clinical application of MHV assessment. However, AIS patients who present with MHVs and without END would be more likely to experience END than those without MHVs. Monitoring the functional status and maintaining a stable level of cerebral perfusion would be a reasonable treatment.

CONCLUSION

The presence of MHVs might be useful in the prediction of END in AIS patients with symptomatic ILASO after r-tPA treatment.

Acknowledgements We thank Lisa Kreiner, PhD, from Liwen Bianji, Edanz Editing China (www.liwenbianji.cn/ac), for editing the English text of a draft of this manuscript.

Contributors Y-LL: designed and conceptualised the study; analysed the data; data acquisition; drafted the manuscript for intellectual content. Y-KC: designed and conceptualised study; analysed the data; data acquisition; revised the manuscript for intellectual content. H-PY, D-HQ, J-FQ, H-HZ, Z-HL, FW, M-QL: analysed data; data acquisition.

Funding This study was supported by the Medical Scientific Research Foundation of Guangdong Province, China (Reference number: A2018322).

Competing interests None declared.

Patient consent for publication Obtained.

Ethics approval This study was approved by the hospital ethics committee (approval number: KYKT2018-002).

Provenance and peer review Not commissioned; externally peer reviewed.

Data availability statement Data are available on reasonable request.

Open access This is an open access article distributed in accordance with the Creative Commons Attribution Non Commercial (CC BY-NC 4.0) license, which permits others to distribute, remix, adapt, build upon this work non-commercially, and license their derivative works on different terms, provided the original work is properly cited, appropriate credit is given, any changes made indicated, and the use is non-commercial. See: <http://creativecommons.org/licenses/by-nc/4.0/>.

ORCID iDs

Yong-Lin Liu <http://orcid.org/0000-0002-6204-4231>

Huo-Hua Zhong <http://orcid.org/0000-0002-0428-2493>

Yang-Kun Chen <http://orcid.org/0000-0003-0824-1442>

REFERENCES

- 1 Thanvi B, Treadwell S, Robinson T. Early neurological deterioration in acute ischaemic stroke: predictors, mechanisms and management. *Postgrad Med J* 2008;84:412–7.
- 2 Ois A, Martinez-Rodriguez JE, Munteis E, *et al*. Steno-occlusive arterial disease and early neurological deterioration in acute ischemic stroke. *Cerebrovasc Dis* 2008;25:151–6.
- 3 Lee S-J, Hong JM, Lee SE, *et al*. Association of fibrinogen level with early neurological deterioration among acute ischemic stroke patients with diabetes. *BMC Neurol* 2017;17:101.
- 4 Arenillas JF, Rovira A, Molina CA, *et al*. Prediction of early neurological deterioration using diffusion- and perfusion-weighted imaging in hyperacute middle cerebral artery ischemic stroke. *Stroke* 2002;33:2197–205.
- 5 Dávalos A, Toni D, Iweins F, *et al*. Neurological deterioration in acute ischemic stroke: potential predictors and associated factors in the European cooperative acute stroke study (ECASS) I. *Stroke* 1999;30:2631–6.
- 6 Weimar C, Mieck T, Buchthal J, *et al*. Neurologic worsening during the acute phase of ischemic stroke. *Stroke* 2005;62:393–7.
- 7 Kwon H-M, Lee Y-S, Bae H-J, *et al*. Homocysteine as a predictor of early neurological deterioration in acute ischemic stroke. *Stroke* 2014;45:871–3.
- 8 Choi K-H, Park M-S, Kim J-T, *et al*. Serum triglyceride level is an important predictor of early prognosis in patients with acute ischemic stroke. *J Neurol Sci* 2012;319:111–6.
- 9 Nam K-W, Kim CK, Kim TJ, *et al*. D-dimer as a predictor of early neurologic deterioration in cryptogenic stroke with active cancer. *Eur J Neurol* 2017;24:205–11.
- 10 Steinke W, Ley SC. Lacunar stroke is the major cause of progressive motor deficits. *Stroke* 2002;33:1510–6.
- 11 Simonsen CZ, Schmitz ML, Madsen MH, *et al*. Early neurological deterioration after thrombolysis: clinical and imaging predictors. *Int J Stroke* 2016;11:776–82.

- 12 Kim J-M, Moon J, Ahn S-W, *et al.* The etiologies of early neurological deterioration after thrombolysis and risk factors of ischemia progression. *J Stroke Cerebrovasc Dis* 2016;25:383–8.
- 13 Seners P, Turc G, Tisserand M, *et al.* Unexplained early neurological deterioration after intravenous thrombolysis: incidence, predictors, and associated factors. *Stroke* 2014;45:2004–9.
- 14 Miyasaka T, Taoka T, Nakagawa H, *et al.* Application of susceptibility weighted imaging (SWI) for evaluation of draining veins of arteriovenous malformation: utility of magnitude images. *Neuroradiology* 2012;54:1221–7.
- 15 Huang P, Chen C-H, Lin W-C, *et al.* Clinical applications of susceptibility weighted imaging in patients with major stroke. *J Neurol* 2012;259:1426–32.
- 16 Kao H-W, Tsai FY, Hasso AN. Predicting stroke evolution: comparison of susceptibility-weighted MR imaging with MR perfusion. *Eur Radiol* 2012;22:1397–403.
- 17 Haacke EM, Mittal S, Wu Z, *et al.* Susceptibility-weighted imaging: technical aspects and clinical applications, part 1. *AJNR Am J Neuroradiol* 2009;30:19–30.
- 18 Sun W, Liu W, Zhang Z, *et al.* Asymmetrical cortical vessel sign on susceptibility-weighted imaging: a novel imaging marker for early neurological deterioration and unfavorable prognosis. *Eur J Neurol* 2014;21:1411–8.
- 19 Cheng B, Schröder N, Forkert ND, *et al.* Hypointense vessels detected by susceptibility-weighted imaging identifies tissue at risk of infarction in anterior circulation stroke. *J Neuroimaging* 2017;27:414–20.
- 20 Yu J, Wang L, Li Z, *et al.* Related factors of asymmetrical vein sign in acute middle cerebral artery stroke and correlation with clinical outcome. *J Stroke Cerebrovasc Dis* 2017;26:2346–53.
- 21 Wang Y, Shi T, Chen B, *et al.* Prominent hypointense vessel sign on susceptibility-weighted imaging is associated with clinical outcome in acute ischaemic stroke. *Eur Neurol* 2018;79:231–9.
- 22 Alawneh JA, Moustafa RR, Baron J-C. Hemodynamic factors and perfusion abnormalities in early neurological deterioration. *Stroke* 2009;40:e443–50.
- 23 Hsu C-Y, Cheng C-Y, Tsai Y-H, *et al.* Perfusion-Diffusion mismatch predicts early neurological deterioration in anterior circulation infarction without thrombolysis. *Curr Neurovasc Res* 2015;12:277–82.
- 24 Siegler JE, Martin-Schild S. Early neurological deterioration (end) after stroke: the end depends on the definition. *Int J Stroke* 2011;6:211–2.
- 25 Park M-G, Yang T-I, Oh S-J, *et al.* Multiple hypointense vessels on susceptibility-weighted imaging in acute ischemic stroke: surrogate marker of oxygen extraction fraction in penumbra? *Cerebrovasc Dis* 2014;38:254–61.
- 26 Puetz V, Dzialowski I, Hill MD, *et al.* The Alberta stroke program early CT score in clinical practice: what have we learned? *Int J Stroke* 2009;4:354–64.
- 27 Listed N. Prognosis of patients with symptomatic vertebral or basilar artery stenosis. The Warfarin-Aspirin symptomatic intracranial disease (WASID) Study Group. *Stroke* 1998;29:1389–92.
- 28 Hacke W, Kaste M, Fieschi C, *et al.* Randomised double-blind placebo-controlled trial of thrombolytic therapy with intravenous alteplase in acute ischaemic stroke (ECASS II). Second European-Australasian acute stroke study Investigators. *Lancet* 1998;352:1245–51.
- 29 Lassalle L, Turc G, Tisserand M, *et al.* Aspects (Alberta stroke program early CT score) assessment of the perfusion-diffusion mismatch. *Stroke* 2016;47:2553–8.
- 30 Staals J, Makin SDJ, Doubal FN, *et al.* Stroke subtype, vascular risk factors, and total MRI brain small-vessel disease burden. *Neurology* 2014;83:1228–34.
- 31 Kesavadas C, Santhosh K, Thomas B. Susceptibility weighted imaging in cerebral hypoperfusion-can we predict increased oxygen extraction fraction? *Neuroradiology* 2010;52:1047–54.
- 32 Xia S, Utriainen D, Tang J, *et al.* Decreased oxygen saturation in asymmetrically prominent cortical veins in patients with cerebral ischemic stroke. *Magn Reson Imaging* 2014;32:1272–6.
- 33 Kim Y-W, Kim HJ, Choi SH, *et al.* Prominent hypointense veins on susceptibility weighted image in the cat brain with acute infarction: DWI, SWI, and PWI. *Acta Radiol* 2014;55:1008–14.
- 34 Luo Y, Gong Z, Zhou Y, *et al.* Increased susceptibility of asymmetrically prominent cortical veins correlates with misery perfusion in patients with occlusion of the middle cerebral artery. *Eur Radiol* 2017;27:2381–90.
- 35 Asdaghi N, Hill MD, Coulter JI, *et al.* Perfusion Mr predicts outcome in high-risk transient ischemic attack/minor stroke: a derivation-validation study. *Stroke* 2013;44:2486–92.
- 36 Verma RK, Hsieh K, Gratz PP, *et al.* Leptomeningeal collateralization in acute ischemic stroke: impact on prominent cortical veins in susceptibility-weighted imaging. *Eur J Radiol* 2014;83:1448–54.