

# Chinese Stroke Association guidelines for clinical management of cerebrovascular disorders: executive summary and 2019 update of clinical management of cerebral venous sinus thrombosis

Yuhua Fan <sup>1</sup>, Jian Yu,<sup>1</sup> Hongbing Chen,<sup>1</sup> Jian Zhang,<sup>1</sup> Jiangang Duan,<sup>2</sup> Dapeng Mo,<sup>3</sup> Wenhao Zhu,<sup>4</sup> Bo Wang,<sup>3</sup> Fubing Ouyang,<sup>1</sup> Yicong Chen,<sup>1</sup> Linfang Lan,<sup>1</sup> Jinsheng Zeng <sup>1</sup>, Chinese Stroke Association Stroke Council CVST Guideline Writing Committee

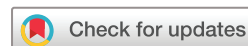**To cite:** Fan Y, Yu J, Chen H, et al. Chinese Stroke Association guidelines for clinical management of cerebrovascular disorders: executive summary and 2019 update of clinical management of cerebral venous sinus thrombosis. *Stroke & Vascular Neurology* 2020;0. doi:10.1136/svn-2020-000358

► Additional material is published online only. To view, please visit the journal online (<http://dx.doi.org/10.1136/svn-2020-000358>).

Received 27 February 2020

Revised 26 March 2020

Accepted 31 March 2020



© Author(s) (or their employer(s)) 2020. Re-use permitted under CC BY-NC. No commercial re-use. See rights and permissions. Published by BMJ.

For numbered affiliations see end of article.

## Correspondence to

Professor Jinsheng Zeng; zengjs@pub.guangzhou.gd.cn

## ABSTRACT

**Aim** Cerebral venous sinus thrombosis (CVST) is a less common cerebrovascular disease that predominantly affects young patients. The incidence of CVST is 2–5/10 000 000/year, accounting for 0.5%–1% of all stroke. To reduce mortality and morbidity associated with CVST, Chinese Stroke Association commissioned the authors to write the current guideline on the management of CVST.

**Methods** PubMed (MEDLINE), CNKI and Wanfang database were searched for studies related to CVST from 1 January 1990 to 31 July 2019. Data were synthesised by evidence tables. Each recommendation was fully discussed by the writing group members and reviewed by Chinese Stroke Association Stroke Fellow Committees. Levels of evidence grading algorithm of Chinese Stroke Association was used to grade each recommendation.

**Results** This guideline mainly focuses on the diagnostic evaluation, therapeutic strategies and secondary prevention of CVST. CT/CTV and MRI/MRV are recommended in the initial imaging evaluation of patients with suspected CVST. Anticoagulation therapy with low-molecular weight heparin should be initiated in patients with CVST immediately. After the acute stage, warfarin is recommended for 3–6 months to prevent the recurrence of CVST and other venous thromboembolic events.

**Conclusions** The guideline summarises the current evidence regarding the management of CVST, and provides references for diagnosis, treatment and secondary prevention of CVST in China.

Cerebral venous sinus thrombosis (CVST) is a particular type of cerebrovascular disease characterised by increased intracranial pressure due to impaired cerebral venous drainage and absorption of cerebrospinal fluid. The incidence of CVST is 2–5/10 000 000/year, accounting for 0.5%–1% of all stroke.<sup>1–9</sup> Recently, the incidence of CVST has been rising with the advent of

diagnostic techniques. Two studies in Iran have reported CVST affects 12.3–13.49/10 000 000/year,<sup>3 10</sup> and another study in Saudi Arabia has shown that CVST affects 70/10 000 000/year.<sup>11</sup> Moreover, the incidence of CVST has also been increasing in Europe and America, approximately 13.2–15.7/10 000 000/year.<sup>12 13</sup> CVST occurs in neonates and juveniles with a frequency of 6.7/10 000 000/year.<sup>1 14 15</sup> The international study of cerebral venous thrombosis has reported 487 of 624 cases occur in patients aged <50 years.<sup>16</sup> During pregnancy, the incidence of CVST is 100/10 000 000, accounting for 5%–20% of all CVST.<sup>4</sup> The epidemiological data of CVST in China are scarce. Nevertheless, CVST is not uncommon in China, especially in women taking oral contraceptives or in the perinatal period. CVST can affect superficial cerebral veins, deep cerebral veins or dural venous sinuses. The isolated thrombosis of superficial cerebral veins is rare. The involvement of superficial veins, for the most part, is caused by the thrombosis of dural venous sinuses. The thrombosis of deep cerebral veins usually occurs in the internal cerebral vein and vein of Galen. About 60% of patients with CVST involve multiple dural venous sinuses, with the superior sagittal sinus the most frequently affected. As there are multiple anatomical anastomoses between cerebral veins and dural venous sinuses, clinical manifestations vary from an asymptomatic state to death, depending on the site of thrombosis and collateral circulation.

This document is the executive summary, and update of the guideline of CVST by

Chinese Stroke Association in 2019. The full text of this guideline is available in the online supplementary material. The intended audiences of this guideline are physicians of neurology and other related disciplines, providing references for the clinical management of CVST in China.

## PART 1: DIAGNOSTIC EVALUATION

CVST can directly increase pressure of venules and capillaries, and can increase intracranial pressure by reducing the absorption of cerebrospinal fluid, leading to the decrease of cerebral artery perfusion, destruction of blood-brain barrier, ischaemic damage or cerebral parenchymal

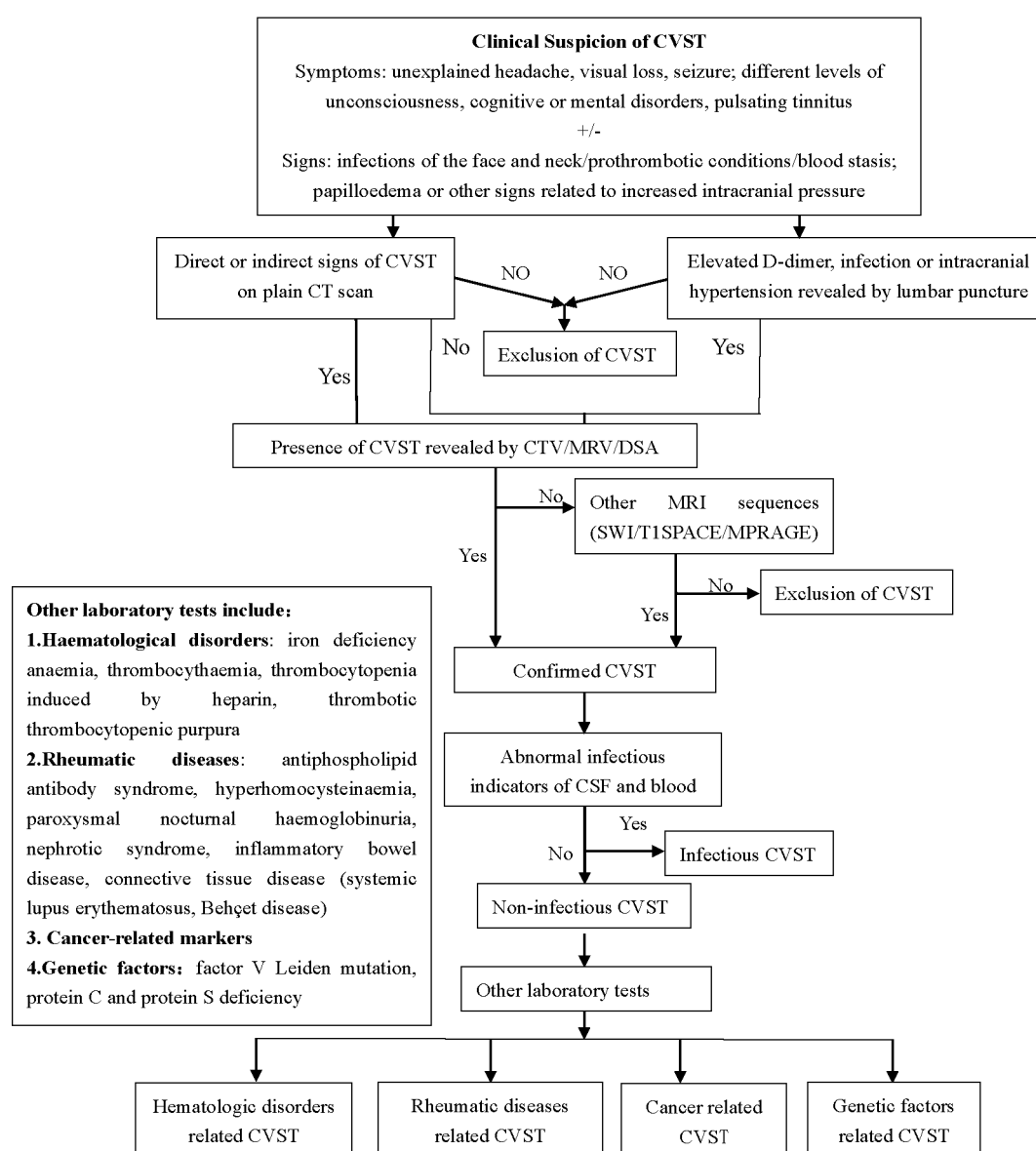
haemorrhage. Therefore, clinical manifestations of CVST mainly depend on the location, nature, extent of venous (sinus) thrombosis and the degree of secondary brain damage. The diagnostic flow chart is shown in [figure 1](#).

## HISTORY AND CLINICAL MANIFESTATIONS

### Recommendation

1. Vigilance should be maintained for CVST. The possibility of CVST should be considered in patients presented with headache, papilloedema or increased intracranial pressure with unknown cause. The screening for CVST is reasonable in patients presented with unexplained seizures (including eclampsia), focal brain injury,

**Figure 1. The Proposed Algorithm for the Diagnosis of CVST**



**Figure 1** The proposed algorithm for the diagnosis of cerebral venous sinus thrombosis (CVST). CTV, compute tomography venography. MRV, magnetic resonance venography. MRV, magnetic resonance venography. DSA, digital subtraction angiography. CSF, cerebrospinal fluid.

different levels of unconsciousness, cognitive disorders, psychosis or dural arteriovenous fistula. (Class I, Level of Evidence C).

## AUXILIARY EXAMINATION

### Recommendation

1. Routine blood tests consisting of a complete blood count, chemistry panel, prothrombin time, activated partial thromboplastin time, plasma protein and connective tissue disease or cancer markers are recommended in patients with suspected CVST. (Class I, Level of Evidence C)
2. Screening for potential prothrombotic factors (eg, antithrombin III, protein C or protein S deficiency, factor V Leiden, prothrombin mutation, anticardiolipin antibody, lupus anticoagulant) is recommended in patients with undetermined aetiology, recurrent CVST or a family history of venous thrombosis, to identify the root cause and select appropriate preventive and therapeutic strategies. (Class IIb, Level of Evidence C)
3. An elevated D-dimer level is considered to support the diagnosis of CVST, but a normal D-dimer level should not exclude CVST, especially in patients presented with isolated headache or chronic symptoms. (Class IIa, Level of Evidence B)
4. Lumbar puncture may identify increased intracranial pressure and underlying causes of CVST (eg, infections). (Class IIa, Level of Evidence C)
5. CT/CTV and MRI/MRV are recommended in the initial imaging evaluation of patients with suspected CVST. MRI/MRV is able to diagnose most of CVST, and is recommended as the best non-invasive imaging in the follow-up of CVST. Contrast-enhanced (CE) MRV is more reliable than time-of-flight MRV. (Class IIa, Level of Evidence C)
6. SWI and T2\*-GRE imaging improve the diagnosis of CVST, especially in patients with isolated cortical venous thrombosis or during acute stage. (Class IIa, Level of Evidence C)
7. CE-3D-MPRAGE and 3D-T1-SPACE are sensitive in detecting isolated cortical venous thrombosis and non-thrombotic sinus stenosis. These techniques may be considered in the differentiation of CVST from other conditions (eg, dural sinus stenosis). (Class IIa, Level of Evidence C)
8. DSA is recommended if the initial imaging evaluation by MRV or CTV is inconclusive or endovascular therapy is being considered. The shortage of DSA in detecting isolated cortical venous thrombosis, and the risks of increased intracranial pressure caused by invasive and improper operation should be considered. (Class IIa, Level of Evidence C)
9. Venous pressure measurements via retrograde venography may be performed in patients with intracranial hypertension and dural venous stenosis. Endovascular therapy may be considered in patients

with significantly increased pressure gradient between the proximal and distal segment to the stenosis. (Class IIa, Level of Evidence C)

10. A follow-up CTV/MRV is recommended in patients with CVST with persistent or evolving symptoms despite the initial imaging results. (Class I, Level of Evidence C)
11. A follow-up CTV/MRV at 3–6 months is reasonable to evaluate the recanalisation of dural sinuses and cortical veins. (Class IIa, Level of Evidence C)

## CAUSES AND RISK FACTORS FOR CVST

### Recommendation

1. The risk factors and causes of CVST are complicated and diverse. It is recommended to screen for the risk factors contributed to prothrombotic conditions and exclude the possibility of infections associated with CVST. (Class I, Level of Evidence B)

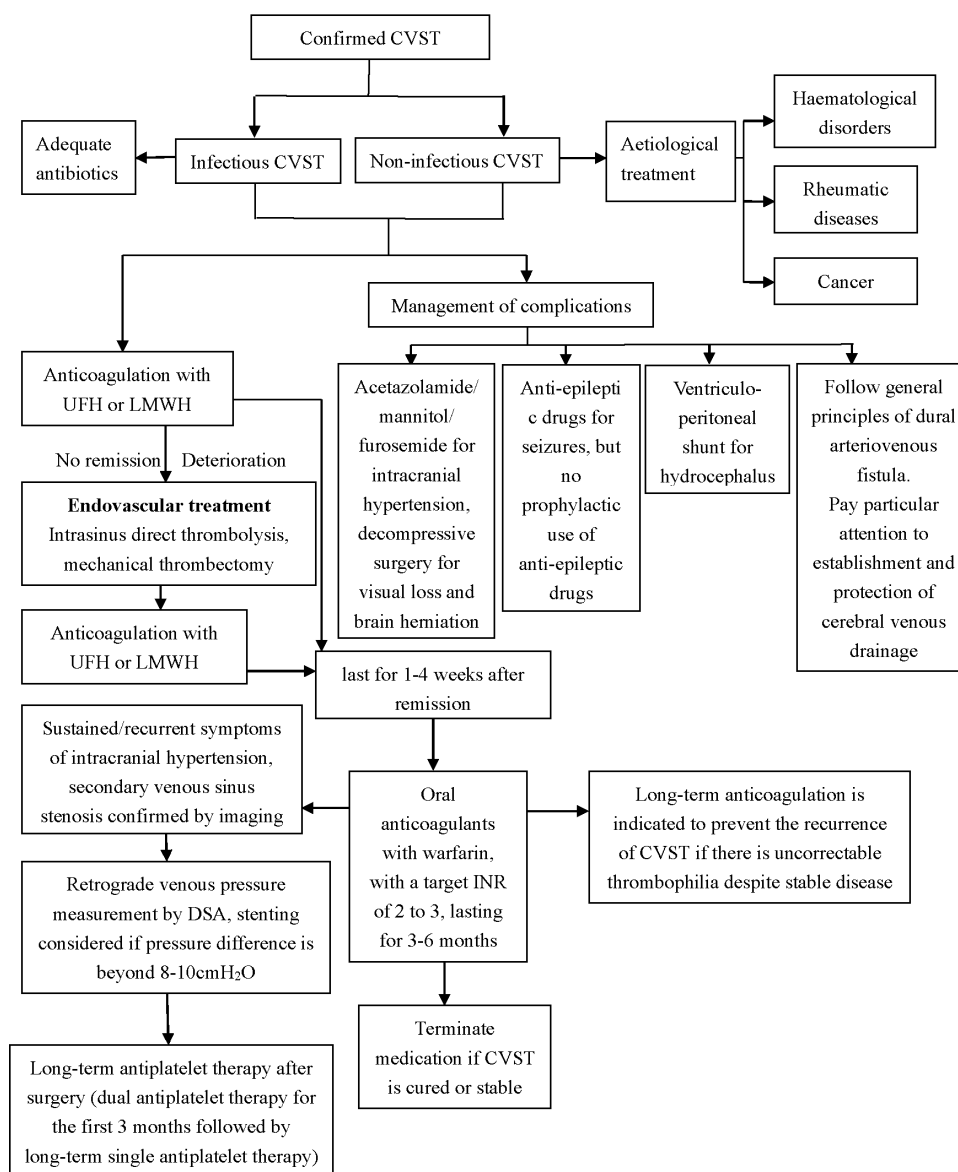
## PART 2: TREATMENT OF CVST

The main treatment of CVST is anticoagulation therapy with either intravenous unfractionated heparin (UFH) or subcutaneous low-molecular weight heparin (LMWH). After the acute stage of CVST, oral anticoagulants such as warfarin should be used for at least 3–6 months. Recently, an exploratory, prospective, randomised trial (RE-SPECT CVT) compared the efficacy and safety of dabigatran with warfarin in patients with CVST for 24 weeks. The result demonstrated both dabigatran and warfarin were safe and effective for preventing recurrent venous thrombotic events in patients with CVST.<sup>17</sup> However, the efficacy of endovascular treatment has not been proved until now. The flow chart of CVST treatment is shown in [figure 2](#).

## ANTICOAGULATION THERAPY

### Recommendation

1. Anticoagulation therapy should be initiated in patients with CVST immediately. (Class I, Level of Evidence B) The safety and efficacy of LMWH is slightly superior to UFH. (Class IIa, Level of Evidence B) LMWH is recommended for the acute management of CVST. The therapeutic dosage of LMWH is 0.4–0.6 mL, injected subcutaneously twice a day. If UFH is used, the initial treatment should at least double the activated partial thromboplastin time, lasting for 1–4 weeks. CVST with minor intracranial haemorrhage or intracranial hypertension is not an absolute contradiction to anticoagulation therapy. (Class IIb, Level of Evidence B)
2. Oral anticoagulants should be initiated after the acute stage of CVST. The most commonly used agent is warfarin, with a target international normalised ratio (INR) of 2–3. The duration of treatment depends on the tendency to thrombosis and the risk of recurrence. (Class IIa, Level of Evidence C). Warfarin is recommended to maintain 3–6 months to prevent the recurrence of CVST and other venous thromboembolic events. (Class IIa, Level of Evidence C) It is under-

**Figure 2. The Proposed Algorithm for the Treatment of CVST**

**Figure 2** The proposed algorithm for the treatment of cerebral venous sinus thrombosis (CVST). INR, international normalised ratio; LMWH, low-molecular weight heparin; UFH, unfractionated heparin.

mined whether recanalisation of the occluded veins or dural sinuses can be considered as an indication for withdrawal of oral anticoagulants. (Class III, Level of Evidence C)

3. Dabigatran may be considered in patients with CVST unsuitable for warfarin. (Class IIa, Level of Evidence B) (New recommendation) Further studies are needed to determine the efficacy of other new oral anticoagulants in CVST. (Class IIb, Level of Evidence C)

## ENDOVASCULAR TREATMENT

### Recommendation

1. Current evidence is not sufficient to recommend the application of intrasinus thrombolysis or mechanical thrombectomy in severe CVST. However, mechanical

thrombectomy can be considered in patients with severe CVST after adequate anticoagulation has failed and there is a need to prevent or treat brain herniation. (Class IIb, Level of Evidence C)

2. Venous pressure measurements via retrograde venography may be performed in patients with intracranial hypertension and dural venous stenosis. Intrasinus stenting may be considered if the pressure gradient between proximal and distal segment to the stenosis is beyond 8–10 mm Hg. (Class IIb, Level of Evidence C)
3. The long-term antithrombotic treatment after the sinus stenting is not clear. According to clinical practice in arterial stenting, it is reasonable to use dual antiplatelet therapy for the first 3 months followed by



single antiplatelet therapy for maintenance. (Class IIb, Level of Evidence C)

## TREATMENT OF CVST DURING PREGNANCY

### Recommendation

1. LMWH is recommended in women with CVST during pregnancy. The safety of LMWH is superior to UFH. Subcutaneous injection of LMWH is recommended throughout the pregnancy (0.4 mL, twice a day), followed by LMWH or warfarin with a target INR of 2–3 for at least 6 weeks postpartum. The total duration of treatment is no less than 6 months. (Class I, Level of Evidence C)

## AETIOLOGICAL TREATMENT

### Recommendation

1. It is recommended to seek and treat the potential causes. Administration of appropriate and adequate antibiotics should be initiated immediately in patients with infection and CVST, as well as surgical removal of sources of infection. (Class I, Level of Evidence C)
2. Patients with CVST with factor V Leiden gene mutation, protein C or protein S deficiency may benefit from long-term therapy with oral anticoagulants. (Class IIa, Level of Evidence C)
3. It is recommended to reduce or avoid the use of oral contraceptives, especially in female patients with a previous history of CVST. (Class I, Level of Evidence C)
4. Pregnancy is not contraindicated in female patients with a history of CVST, but patients should be informed of the high risk of recurrent CVST or loss of pregnancy. (Class IIa, Level of Evidence C)

## MANAGEMENT OF COMPLICATIONS

### Recommendation

1. Patients with severe intracranial hypertension and impending cerebral herniation should be treated immediately. Use of decompressive craniectomy, ventriculoperitoneal shunt or haematoma evacuation may be considered. (Class IIa, Level of Evidence C)
2. Patients with increased intracranial pressure and progressive visual loss should be treated early to save the vision. Decompressive surgery includes optic nerve sheath fenestration and ventriculoperitoneal shunt. (Class IIa, Level of Evidence C)
3. It is reasonable to initiate short-term dehydration therapy with mannitol or furosemide, to gain time for surgery in patients with intracranial hypertension, progressive visual loss or cerebral herniation. Excessive dehydration is prohibited as it can lead to blood concentration and aggravation of CVST. Acetazolamide may be considered in certain patients to reduce intracranial pressure by decreasing the secretion of cerebrospinal fluid. (Class IIb, Level of Evidence C)
4. In patients with a first seizure and parenchymal lesion, antiepileptic therapy should be initiated immediately.

(Class I, Level of Evidence B) In patients with a first seizure without parenchymal lesion, early initiation of antiepileptic drugs may be beneficial. (Class III, Level of Evidence C) Prophylactic use of antiepileptic drugs in patients with CVST is not beneficial. (Class III, Level of Evidence C)

5. The treatment of dural arteriovenous fistula induced by CVST can refer to the general principles of dural arteriovenous fistula. More attention should be given to the establishment and protection of cerebral venous drainage. (Class IIb, Level of Evidence C)

## OTHER TREATMENT

### Recommendation

1. In patients with clinical deterioration despite adequate anticoagulation therapy, and without severe intracranial haemorrhage, direct intrasinus thrombolysis can be carefully performed under close supervision. (Class IIb, Level of Evidence C) Current evidence does not support the use of systemic thrombolysis in CVST. (Class III, Level of Evidence C)
2. Current evidence does not support the routine use of antiplatelet drugs or de-fibrin therapy in CVST, unless it is indicated for other underlying diseases. (Class III, Level of Evidence C)
3. Routine use of steroid in CVST is not beneficial, unless it is indicated for other underlying diseases. (Class III, Level of Evidence B)
4. It is recommended to use antibiotics in patients with CVST and infection for 3–8 weeks. (Class I, Level of Evidence C)

## PART 3: SECONDARY PREVENTION OF CVST

### Recommendation

1. If patients with a history of CVST have a recurrent and constant headache, it is necessary to evaluate the recurrence of CVST and pay attention to intracranial hypertension. (Class I, Level of Evidence C)
2. To prevent recurrence of CVST, it is important to eliminate the root cause. (Class I, Level of Evidence C) It is beneficial to seek and treat prothrombotic conditions, such as protein C, protein S deficiency, antiphospholipid syndrome and factor V Leiden mutation, for preventing recurrence of CVST in certain patients. (Class IIa, Level of Evidence C)
3. Long-term oral anticoagulants may be considered in patients with recurrent CVST and severe thrombophilia, with a target INR of 2–3. (Class IIa, Level of Evidence C)

### Author affiliations

<sup>1</sup>Department of Neurology, The First Affiliated Hospital, Sun Yat-sen University; Guangdong Provincial Key Laboratory for Diagnosis and Treatment of Major Neurological Diseases, National Key Clinical Department and Key Discipline of Neurology, Guangzhou, China

<sup>2</sup>Department of Neurology and Department of Emergency, Xuanwu Hospital, Capital Medical University, Beijing, China

<sup>3</sup>Department of Interventional Neuroradiology, Beijing Tiantan Hospital, Capital Medical University, Beijing, China

<sup>4</sup>Department of Neurology, Tongji Hospital, Tongji Medical College, Huazhong University of Science and Technology, Wuhan, China

**Collaborators** Chinese Stroke Association Stroke Council Guideline Writing Committee: Yongjun Wang (yongjunwang@ncrcnd.org.cn, Department of Neurology, Beijing Tiantan Hospital, Capital Medical University, Beijing, China), Jizong Zhao (zhaojz205@163.com/zhaojz@public.bta.net.cn, Department of Neurosurgery, Beijing Tiantan Hospital, Capital Medical University, Beijing, China), Vice-Chairman: Anding Xu (tli@jnu.edu.cn, Department of Neurology and Stroke Center, the First Affiliated Hospital, Jinan University, Guangzhou, China), Members of Academic Committee: Kangning Chen (ckn\_640827@126.com, Department of Neurology, The Southwest Hospital, the First Affiliated Hospital of Third Military Medical University, Chongqing, China), Junbo Ge (ge.junbo@zs-hospital.sh.cn, Shanghai Institute of Cardiovascular Diseases, Department of Cardiology, Zhongshan Hospital, Fudan University, Shanghai, China), Li Guo (guoli6@163.com, Department of Neurology, The Second Hospital of Hebei Medical University, Shijiazhuang, China), Li He (heli2003new@126.com, Department of Neurology, West China Hospital, Sichuan University, Chengdu, China), Bo Hu (hubo@hust.edu.cn, Department of Neurology, Union Hospital, Tongji Medical College, Huazhong University of Science and Technology (HUST), Wuhan, China), Yong Huo (huoyong@263.net.cn, Department of Cardiology, Peking University First Hospital, Beijing, China), Linong Ji (jilin@bjmu.edu.cn, Department of Endocrinology and Metabolism, Peking University People's Hospital, Medicine at Peking University, Beijing, China), Xunming Ji (robertjxm@hotmail.com/jixunming@vip.163.com, Department of Neurosurgery, Xuanwu Hospital, Capital University of Medicine, Beijing, China), Tielin Li (lielin2013@126.com/tielin.li@tom.com, Zhujiang Hospital of Southern Medical University, Guangzhou, China), Liping Liu (lipingsister@gmail.com, Department of Neurology, Beijing Tiantan Hospital, Capital Medical University, Beijing, China), Benyan Luo (luobenyan@zju.edu.cn, Department of Neurology, First Affiliated Hospital of Zhejiang University, Hangzhou, China), Zhongrong Miao (zhongrongm@163.com, Department of Interventional Neuroradiology, Beijing Tiantan Hospital, Capital Medical University, Beijing, China), Xiaoyuan Niu (niuxiaoyuan1958@163.com, Department of Neurology, First Hospital of Shanxi Medical University, Taiyuan, China), Bin Peng (pengbin3@hotmail.com, Department of Neurology, Peking Union Medical College Hospital, Peking Union Medical College and Chinese Academy of Medical Sciences, Beijing, China), Dingfeng Su (dfs@smmu.edu.cn, Department of Pharmacology, the Second Military Medical University (SMMU), Shanghai, China), Beisha Tang (bstang7398@163.com, Department of Neurology, Xiangya Hospital, Central South University, Changsha, China), Chen Wang (wangchen-tr2002@163.com, Beijing Tiantan Hospital, Capital Medical University, Beijing, China), Ning Wang (nwang900@yahoo.com, Department of Neurology and Institute of Neurology, First Affiliated Hospital of Fujian Medical University, Fuzhou, China), Shuo Wang (captain9858@vip.sina.com, Department of Neurosurgery, Beijing Tiantan Hospital, Capital Medical University, Beijing, China), Wei Wang (wwang@vip.126.com/wwang@tjh.tjmu.edu.cn, Tongji Hospital, Tongji Medical College, Huazhong University of Science and Technology, Wuhan, China), Xin Wang (wang.xin@zs-hospital.sh.cn, Department of Neurology, Zhongshan Hospital, Fudan University, Shanghai, China), Yilong Wang (yilong528@aliyun.com, Department of Neurology, Beijing Tiantan Hospital, Capital Medical University, Beijing, China), Shizheng Wu (wushizheng2005@hotmail.com, Qinghai Province People's Hospital, Xining, China), Peng Xie (xiepeng@cqmu.edu.cn, Chongqing Medical University (CQMU), Chongqing, China), Yuming Xu (13903711125@126.com/xym13903711125@126.com, Department of Neurology, the First Affiliated Hospital of Zhengzhou University, Zhengzhou, China), Yun Xu (xuyun20042001@aliyun.com, Department of Neurology, Drum Tower Hospital, Medical School of Nanjing University, Nanjing, China), Yi Yang (doctoryangyi@163.com/doctor\_yangyi@hotmail.com, Department of Neurology, the First Hospital of Jilin University, Changchun, China), Jinsheng Zeng (zengjs@pub.guangzhou.gd.cn, Department of Neurology, The First Affiliated Hospital, Sun Yat-sen University; Guangdong Provincial Key Laboratory of Diagnosis and Treatment of Major Neurological Diseases, National Key Clinical Department and Key Discipline of Neurology, Guangzhou, 510080, China), Chaodong Zhang (scdzhang@163.com, the First affiliated Hospital of China Medical University, Shenyang, China), Tong Zhang (zt61611@sohu.com, Capital Medical University School of Rehabilitation Medicine, China Rehabilitation Research Center, Beijing, China), Zhuo Zhang (zzhuo005@gmail.com, Beijing Anzhen Hospital, Capital Medical University, Beijing, China), Gang Zhao (zhaogang@fmmu.edu.cn, Department of Neurology, Xijing Hospital, The 4th Military Medical University, Xi'an, China), Xingquan Zhao (zxq@vip.163.com, Department of Neurology, Beijing Tiantan Hospital, Capital Medical University, Beijing, China).

**Contributors** JZ\* designed the protocol and framework and also participated in revision. YF drafted the sections of diagnosis strategy and general management and revised the whole manuscript. DM and BW drafted the section of epidemiology. HC and JZ# drafted the section of imaging examination in diagnosis. WZ drafted the section of laboratory examination in diagnosis. JY and LL drafted the section of medicine treatment. JD, YC and FO drafted the section of endovascular treatment and prevention. JZ reviewed all the studies' design and interpretation, and confirmed the level of evidence and classification. note: JZ \* refers to Jinsheng Zeng, JZ# refers to Jian Zhang

**Funding** This research received specific funding from Chinese Stroke Association Guidelines Writing Committee.

**Competing interests** None declared.

**Patient consent for publication** Not required.

**Provenance and peer review** Commissioned; externally peer reviewed.

**Open access** This is an open access article distributed in accordance with the Creative Commons Attribution Non Commercial (CC BY-NC 4.0) license, which permits others to distribute, remix, adapt, build upon this work non-commercially, and license their derivative works on different terms, provided the original work is properly cited, appropriate credit is given, any changes made indicated, and the use is non-commercial. See: <http://creativecommons.org/licenses/by-nc/4.0/>.

#### ORCID iDs

Yuhua Fan <http://orcid.org/0000-0002-1172-1490>

Jinsheng Zeng <http://orcid.org/0000-0003-4280-0439>

#### REFERENCES

- 1 Stam J. Thrombosis of the cerebral veins and sinuses. *N Engl J Med* 2005;352:1791–8.
- 2 Bousser M-G, Ferro JM. Cerebral venous thrombosis: an update. *Lancet Neurol* 2007;6:162–70.
- 3 Janghorbani M, Zare M, Saadatnia M, et al. Cerebral vein and dural sinus thrombosis in adults in Isfahan, Iran: frequency and seasonal variation. *Acta Neurol Scand* 2008;117:117–21.
- 4 Weimar C, Masuhr F, Hajjar K. Diagnosis and treatment of cerebral venous thrombosis. *Expert Rev Cardiovasc Ther* 2012;10:1545–53.
- 5 Filippidis A, Kapsalaki E, Patramani G, et al. Cerebral venous sinus thrombosis: review of the demographics, pathophysiology, current diagnosis, and treatment. *Neurosurg Focus* 2009;27:E3.
- 6 Medel R, Monteith SJ, Crowley RW, et al. A review of therapeutic strategies for the management of cerebral venous sinus thrombosis. *Neurosurg Focus* 2009;27:E6.
- 7 Chik Y, Gottesman RF, Zeiler SR, et al. Differentiation of transverse sinus thrombosis from congenitally atretic cerebral transverse sinus with CT. *Stroke* 2012;43:1968–70.
- 8 Rahman M, Velat GJ, Hoh BL, et al. Direct thrombolysis for cerebral venous sinus thrombosis. *Neurosurg Focus* 2009;27:E7.
- 9 Saposnik G, Barinagarrementeria F, Brown RD, et al. Diagnosis and management of cerebral venous thrombosis: a statement for healthcare professionals from the American heart Association/American stroke association. *Stroke* 2011;42:1158–92.
- 10 Ghiasian M, Mansour M, Mazaheri S, et al. Thrombosis of the cerebral veins and sinuses in Hamadan, West of Iran. *J Stroke Cerebrovasc Dis* 2016;25:1313–9.
- 11 Daif A, Awada A, al-Rajeh S, et al. Cerebral venous thrombosis in adults. A study of 40 cases from Saudi Arabia. *Stroke* 1995;26:1193–5.
- 12 Coutinho JM, Zuurbier SM, Aramideh M, et al. The incidence of cerebral venous thrombosis: a cross-sectional study. *Stroke* 2012;43:3375–7.
- 13 Devasagayam S, Wyatt B, Leyden J, et al. Cerebral venous sinus thrombosis incidence is higher than previously thought: a retrospective population-based study. *Stroke* 2016;47:2180–2.
- 14 Agnelli G, Verso M. Epidemiology of cerebral vein and sinus thrombosis. *Front Neurol Neurosci* 2008;23:16–22.
- 15 deVeber G, Andrew M, Adams C, et al. Cerebral sinovenous thrombosis in children. *N Engl J Med* 2001;345:417–23.
- 16 Ferro JM, Canhã P, Stam J, et al. Prognosis of cerebral vein and dural sinus thrombosis: results of the International study on cerebral vein and dural sinus thrombosis (ISCVT). *Stroke* 2004;35:664–70.
- 17 Ferro JM, Coutinho JM, Dentali F, et al. Safety and efficacy of dabigatran etexilate vs Dose-Adjusted warfarin in patients with cerebral venous thrombosis: a randomized clinical trial. *JAMA Neurol* 2019;76. doi:10.1001/jamaneurol.2019.2764. [Epub ahead of print: 03 Sep 2019].