


# Application of bedside HINTS, ABCD<sup>2</sup> score and truncal ataxia to differentiate cerebellar–brainstem stroke from vestibular neuritis in the emergency room

Xinmin Liu,<sup>1</sup> Zhaoxia Li,<sup>1,2,3</sup> Yi Ju,<sup>1,2,3</sup> Xingquan Zhao <sup>1,2,3,4,5</sup>

**To cite:** Liu X, Li Z, Ju Y, *et al.*

Application of bedside HINTS, ABCD<sup>2</sup> score and truncal ataxia to differentiate cerebellar–brainstem stroke from vestibular neuritis in the emergency room. *Stroke & Vascular Neurology* 2024;**9**: e002779. doi:10.1136/svn-2023-002779

► Additional supplemental material is published online only. To view, please visit the journal online (<https://doi.org/10.1136/svn-2023-002779>).

XL and ZL contributed equally.

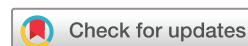XL and ZL are joint first authors.

Received 12 August 2023

Accepted 17 February 2024

Published Online First

26 March 2024



© Author(s) (or their employer(s)) 2024. Re-use permitted under CC BY-NC. No commercial re-use. See rights and permissions. Published by BMJ Group.

For numbered affiliations see end of article.

## Correspondence to

Dr Xingquan Zhao;  
zxq@vip.163.com

Dr Yi Ju; juyi1226@vip.163.com

## ABSTRACT

**Background and purpose** Acute vestibular syndrome (AVS) typically manifests as isolated dizziness or vertigo with no apparent neurological impairments. However, distinguishing life-threatening stroke from innocuous peripheral vestibular lesions in the emergency room (ER) remains challenging. This study aimed to explore the ability of the head impulse–nystagmus–test of skew (HINTS) combined with truncal ataxia or ABCD<sup>2</sup> score to differentiate stroke from peripheral vestibular disease in patients with AVS in the ER.

**Methods** We prospectively recruited 121 patients with AVS from December 2022 to June 2023, 69 of whom presented with vestibular neuritis (VN) and the remaining with posterior circulation stroke (PCS). We analysed the HINTS results, truncal ataxia and ABCD<sup>2</sup> score and compared the sensitivity and specificity among HINTS, truncal ataxia, ABCD<sup>2</sup> score and their combinations using the McNemar test for paired samples.

**Results** HINTS combined with grade 2–3 truncal ataxia achieved significantly higher sensitivity than that of isolated HINTS in differentiating PCS from VN (100% vs 88.5%,  $p=0.031$ ). The specificity of HINTS plus grade 2–3 truncal ataxia did not significantly differ from that of isolated HINTS ( $p=0.125$ ); however, the combination of ABCD<sup>2</sup> score and HINTS did not improve the diagnostic accuracy. The sensitivity of ABCD<sup>2</sup> score  $\geq 4$  plus grade 2–3 truncal ataxia was significantly higher than those of isolated ABCD<sup>2</sup> score  $\geq 4$  or isolated grade 2–3 truncal ataxia ( $p=0.016$  and  $p<0.001$ , respectively) and not significantly lower than that of isolated HINTS ( $p=0.508$ ).

**Conclusion** Compared with the ABCD<sup>2</sup> score, the truncal ataxia is of more valuable assistance to HINTS in differentiating PCS. Although the combination of ABCD<sup>2</sup> score and truncal ataxia has a significant implication, it is not a replacement for HINTS.

## INTRODUCTION

Acute vestibular syndrome (AVS), characterised as acute persisting vertigo or dizziness, is primarily caused by benign vestibular neuritis (VN) or life-threatening posterior circulation stroke (PCS).<sup>1</sup> Vertigo or dizziness due to PCS may accompany various focal neurological deficits based on the structures

## WHAT IS ALREADY KNOWN ON THIS TOPIC

⇒ Head impulse–nystagmus–test of skew (HINTS) examinations play an important role in the differential diagnosis of acute dizziness in the emergency room (ER); however, the rate of utilisation in the ER is still low.

## WHAT THIS STUDY ADDS

⇒ By combining HINTS with grade 2–3 truncal ataxia, we achieved a significantly higher sensitivity than that of isolated HINTS. The sensitivity of ABCD<sup>2</sup> score  $\geq 4$  plus grade 2–3 truncal ataxia was significantly higher than those of isolated ABCD<sup>2</sup> score  $\geq 4$  or isolated grade 2–3 truncal ataxia and not significantly lower than that of isolated HINTS.

## HOW THIS STUDY MIGHT AFFECT RESEARCH, PRACTICE OR POLICY

⇒ Combining truncal ataxia with HINTS will be a valuable tool for differentiating posterior circulation stroke in the ER with higher accuracy. The combination of ABCD<sup>2</sup> score and truncal ataxia also plays an important role.

involved (eg, dysarthria, cranial nerve deficits, Horner's syndrome and appendicular ataxia).<sup>2</sup> However, approximately 25% of PCS may present with isolated vertigo or dizziness without additional typical neurological symptoms or signs, predominantly involving the brainstem or cerebellum.<sup>3</sup> Distinguishing between cerebellar–brainstem stroke and VN in the emergency room (ER) remains challenging.

A clinical assessment of head impulse–nystagmus–test of skew (HINTS) is introduced to differentiate stroke in patients with AVS.<sup>4,5</sup> HINTS has demonstrated excellent accuracy and even outperformed early diffusion-weighted imaging (DWI) in MRI within 48 hours postonset.<sup>4</sup> Previous meta-analyses have revealed that the diagnostic efficacy of HINTS examinations conducted by ER

physicians or non-subspecialist clinicians was significantly inferior to those conducted by specialised neurologists.<sup>6,7</sup> Due to the limited knowledge, inadequate patient tolerance, lack of targeted training and insufficient confidence, the application of HINTS by non-subspecialist clinicians or ER physicians in real-world settings is low.<sup>8,9</sup> Therefore, it is imperative to optimise HINTS by integrating it with other easily accessible clinical assessments in the ER.

Severe truncal ataxia is a sign of the vestibulospinal reflex, which frequently presents in PCS.<sup>10</sup> Physicians who are not specialised in vestibular disorders may overlook the evaluation of truncal coordination due to the patient's severe dizziness. Previous studies have illustrated that truncal ataxia alone or combined with subitems of HINTS reached 100% sensitivity in differentiating cerebellar/brainstem stroke.<sup>11,12</sup> Another easily available substitute to HINTS is the ABCD<sup>2</sup> score, which is effective in identifying patients at high risk of stroke following a transient ischaemic attack (TIA) or minor stroke,<sup>13,14</sup> including cases where the presenting symptoms concerning for TIA are dizziness/vertigo.<sup>15</sup> However, whether truncal ataxia or ABCD<sup>2</sup> score is more effective in optimising HINTS remains to be determined. In contrast to the high demand for specific skills and compliance of patients during HINTS assessment, truncal ataxia and ABCD<sup>2</sup> score are both much easier to evaluate but have less accuracy.<sup>12,16</sup> Whether the combined application of truncal ataxia and ABCD<sup>2</sup> score could differentiate stroke in acute dizziness remains uninvestigated.

Therefore, in this study, we aimed to optimise HINTS using the truncal ataxia or ABCD<sup>2</sup> score, evaluate the ability of truncal ataxia plus ABCD<sup>2</sup> score to identify PCS, and obtain a more accessible and reliable clinical assessment to distinguish PCS among patients with AVS in the ER.

## METHODS

### Study population and design

This was a prospective observational study conducted between December 2022 and June 2023 in the independent neurology ER at Beijing Tiantan hospital. Consecutive patients who visited the ER with AVS defined as new spontaneous and persisting vertigo, dizziness or imbalance (lasting for >24 hours) were enrolled. Patients who reached below 24 hours following the onset of their symptoms were evaluated on admission and followed up in the emergency observation room. All patients were admitted within 7 days of symptoms onset.

The exclusion criteria were as follows: (1) symptoms remission in less than 24 hours postadmission; (2) accompanied with major deficits such as unconsciousness, aphasia or hemiparesis at initial visit (small deficits such as small limb ataxia, sensory symptoms or mild dysarthria were not excluded); (3) missing MRI data, including DWI to confirm the final diagnosis and (4) other or unclear aetiology that did not meet the diagnostic criteria of VN

or PCS. Finally, patients diagnosed with VN and cerebellar–brainstem ischaemic stroke were included.

### Clinical information and assessment

The demographic and clinical information, including systolic blood pressure (SBP), diastolic blood pressure (DBP), smoking and drinking status, clinical symptoms and medical history, was collected at the initial ER visit. Smoking was defined as having smoked at least 100 cigarettes throughout an individual's lifespan.<sup>17</sup> Drinking was defined as the ingestion of ≥30 g/week for ≥1 year.<sup>17</sup> The ABCD<sup>2</sup> score was a stroke risk prediction score ranging from 0 to 7 based on age, blood pressure, clinical features, duration of symptoms and diabetes, and started at 2 due to the requirement for persistent dizziness in our study and was assessed as previously described.<sup>15</sup>

On admission, the patients underwent the following neuro-otological tests: (1) gaze-evoked nystagmus observation; (2) clinical horizontal head impulse test (HIT; if corrective saccade occurred, it was judged as positive, while when no corrective saccade occurred, it was negative)<sup>18</sup>; and (3) skew deviation using the alternate cover test. Any of the following signs indicated the presence of central nystagmus: (1) vertical nystagmus; (2) isolated torsional nystagmus or (3) bidirectional gaze-evoked nystagmus.<sup>19,20</sup> HINTS was classified as central if at least one of the following three components was observed: central nystagmus, negative HIT or skew deviation. HINTS was categorised as peripheral when it exhibited all the following characteristics: positive HIT, no or unidirectional nystagmus and no skew deviation. Truncal ataxia was also assessed as grade 1 (mild and moderate imbalance when walking independently), grade 2 (severe imbalance when standing, but cannot walk without support) or grade 3 (falling from upright posture). For accurate evaluation, all patients must try to walk instead of just subjectively considering that the patient was 'unable to walk'.<sup>10</sup> and were required to stand promptly from the supine position, ensuring a continuous motion without any interruptions. We also conducted a range of general neurological tests, namely evaluations of hearing, cranial nerves, muscle strength, sensation, limb coordination and balance. All these exams were performed in the neurology ER by a specialised and trained neurologist who was blinded to the MRI and caloric test results. Another neurologist, also blinded to imaging results, re-evaluated the patients' performance and reviewed the results of these exams within 24 hours of admission. The two neurologists have, respectively, been engaged in neurovestibular specialty for 6 and 12 years. Through theoretical research, instructional videos and bedside teaching, they have gained proficiency in using HINTS assessment in clinical settings.

All patients underwent MRI with DWI sequences postonset. In cases when patients exhibited clinical signs suggestive of central lesions or new neurological symptoms during hospitalisation but with initial negative DWI, a repeated follow-up delayed MRI scan was conducted

after 48 hours postonset. The lesions on DWI were double-confirmed by radiological reports and a clinical neurologist. For DWI-negative patients, caloric tests were performed to evaluate the vestibular function and further confirm the VN diagnosis. Patients with VN were also assigned to the neurology outpatient department and underwent further follow-up for new neurological deficits and improvement of vestibular symptoms for more than 1-month postonset.

### Diagnosis of PCS and VN

The diagnosis of VN was made based on the following diagnostic criteria for acute unilateral vestibulopathy<sup>21</sup>: (1) presence of unidirectional horizontal-torsional nystagmus; (2) an abnormal HIT result manifesting as ipsilateral findings in the direction of the slow phase of nystagmus or impaired semicircular function in caloric tests; (3) no evidence of acute central neurological symptoms/signs or acute audiological symptoms and (4) normal MRI-DWI results. The diagnosis of PCS was made according to the presence of lesions on DWI located in the cerebellum and/or brainstem.

### Statistical analysis

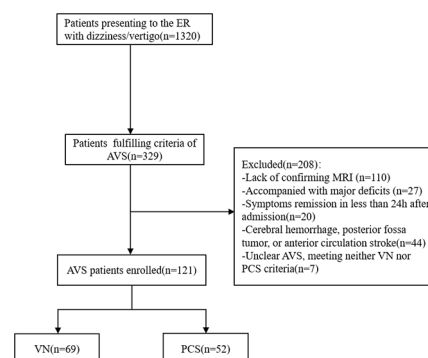
The patients were divided into two groups, namely VN and PCS. Continuous variables were described as the means  $\pm$  standard deviation (SD) or the medians (interquartile range [IQR]) depending on whether the distribution of continuous variables were normal. If the data were normally distributed, the comparisons were analysed using Student's t-test, otherwise the Mann-Whitney U test was used. Categorical variables were described as frequencies with percentages and were compared using the  $\chi^2$  test. As part of the receiver operating characteristic (ROC) analysis, sensitivity versus 1-specificity for PCS was graphed using the ABCD<sup>2</sup> score at various numerical thresholds ranging from  $\geq 2$  to  $\geq 7$ . Comparisons of sensitivity/specificity among HINTS, ABCD<sup>2</sup> score, truncal ataxia and their combinations were performed using the McNemar test for paired samples, applying the Yates continuity correction.<sup>22</sup>

A  $p < 0.05$  was considered statistically significant. All analyses were performed by using the SPSS software (V.24.0; IBM).

## RESULTS

### Demographic information and clinical characteristics

A total of 121 patients were enrolled in the analysis (figure 1), of whom 66.1% (80/121) were males with a median age of 55.0 years (IQR 40.0–64.0 years); 69 patients were diagnosed as VN and 52 as PCS. Among the 52 patients with PCS, the vascular territories included posterior inferior cerebellar artery (PICA) (31/52, 59.6%), anterior inferior cerebellar artery (AICA) (11/52, 21.2%), superior cerebellar artery (SCA) (3/52, 5.8%), basilar artery (BA) (1/52, 1.9%) or multiterritory (6/52, 11.5%). Infarcts were located in the cerebellum (37/52, 71.2%), medulla (5/52,



**Figure 1** Flow chart of the patients selection. AVS, acute vestibular syndrome; ER, emergency room; PCS, posterior circulation stroke; VN, vestibular neuritis.

9.6%), pons (1/52, 1.9%), cerebellum and medulla (4/52, 7.7%), cerebellum and pons (4/52, 7.7%) or in the medulla and pons (1/52, 1.9%) (online supplemental table 1).

Patients in the PCS group were more likely to be older with higher SBP and DBP and increased vascular risk factors, such as smoking, drinking, diabetes, hypertension and history of ischaemic stroke (all  $p < 0.05$ ) (table 1). False-negative MRI was obtained in 7.14% (4/56) of patients 8–24 hour postsymptom onset. Repeated MRI was performed, on average, 6 days later, with a range of 2–8 days, to confirm the presence of stroke. The mean duration (median (IQR)) for the diagnostic stroke MRI was 73.5 (26.5–144.0) hours. All patients underwent MRI within 14 days of symptoms onset.

### Bedside HINTS and truncal ataxia in PCS and VN

Among the 121 patients, 65.3% (79/121) presented with positive HIT (table 2). All patients with VN had a positive HIT while 10 (19.2%) patients with PCS exhibited a positive HIT. Among these 10 patients, 5 had infarcts located within the AICA territory, while the remaining 5 had cerebellar or medulla infarcts with a mass effect on the cerebellopontine angle structure in the PICA territory. We observed that 30.8% of patients with PCS had central nystagmus, 5.8% (3/52) had vertical nystagmus, 5.8% (3/52) had isolated torsional nystagmus and 19.2% (10/52) had bidirectional nystagmus. Skew deviation was detected only in 13.5% of PCS patients. HINTS-central was detected in 88.5% (46/52) of patients with PCS but was not detected in patients with VN. HINTS yielded a sensitivity of 88.5% (95% CI 75.9% to 95.2%) and specificity of 100.0% (95% CI 93.4% to 100.0%) in differentiating PCS. After excluding patients without nystagmus, HINTS yielded a sensitivity of 89.1% (95% CI 75.6% to 95.9%) and specificity of 100.0% (95% CI 93.1% to 100.0%) (table 3).

Grade 3 truncal ataxia never occurred in the VN group. Grade 3 truncal ataxia was reported in 63.5% (33/52) of patients with PCS. Grade 2 truncal ataxia



**Table 1** Baseline characteristics of the total participants

Variables	Total N=121	VN N=69	PCS N=52	P value
Age, median (IQR)	55.0 (40.0–64.0)	47.0 (36.0–59.5)	61.0 (52.3–68.8)	<0.001
Males, n (%)	80 (66.1)	38 (55.1)	42 (80.8)	0.570
SBP, median (IQR)	134.0 (120.0–158.0)	120.0 (115.5–140.0)	156.0 (137.0–177.5)	<0.001
DBP, median (IQR)	77.0 (70.0–94.5)	70.0 (69.5–79.5)	92.0 (80.0–103.0)	<0.001
Onset to admission time (hour), median (IQR)	24.0 (12.0–72.0)	24.0 (12.0–48.0)	31.0 (12.3–72.0)	0.188
Onset to MRI time (hour), median (IQR)	144.0 (56.0–216.0)	170.0 (120.0–264.0)	73.5 (26.5–144.0)	<0.001
Smoking, n (%)	35 (28.9)	5 (7.2)	30 (57.7)	<0.001
Drinking, n (%)	9 (7.4)	1 (1.4)	8 (15.4)	0.004
Diabetes, n (%)	31 (25.6)	9 (13.0)	22 (42.3)	<0.001
Hypertension, n (%)	49 (40.5)	16 (23.2)	33 (63.5)	<0.001
Dyslipidaemia, n (%)	9 (7.4)	5 (7.2)	4 (7.7)	1.000
History of ischaemic stroke, n (%)	9 (7.4)	2 (2.9)	7 (13.5)	0.038
CHD, n (%)	8 (6.6)	2 (2.9)	6 (11.5)	0.073

CHD, coronary heart disease; DBP, diastolic blood pressure; PCS, posterior circulation stroke; SBP, systolic blood pressure; VN, vestibular neuritis.

was detected in both VN and PCS, accounting for 5.8% (4/69) and 17.3% (9/52) of cases, respectively. The presence of grade 3 truncal ataxia showed a sensitivity of 63.5% (95% CI 48.9% to 76.0%) and specificity of 100.0% (95% CI 93.4% to 100.0%) (table 3). While grade 2-3 truncal ataxia acted as a cut-off, the sensitivity was 80.8% (95% CI 67.0% to 89.9%) and specificity of 94.2% (95% CI 85.1% to 98.1%).

#### ABCD<sup>2</sup> score performance in identifying PCS

The ROC curve for ABCD<sup>2</sup> score, used to predict PCS, demonstrated an area under the curve (AUC) of 0.843 (95% CI 0.770 to 0.916;  $p<0.001$ ) (figure 2). We respectively assessed the sensitivity and specificity of ABCD<sup>2</sup> score  $\geq 3$  and ABCD<sup>2</sup> score  $\geq 4$ . ABCD<sup>2</sup> score  $\geq 3$  reached a sensitivity of 90.4% (95% CI 78.2% to 96.4%) and a specificity of 52.2% (95% CI 39.9% to

**Table 2** Clinical assessments of the enrolled patients

Variables	Total N=121	VN N=69	PCS N=52	P value
HIT positive, n (%)	79 (65.3)	69 (100)	10 (19.2)	<0.001
Nystagmus, n (%)				<0.001
No	9 (7.4)	3 (4.3)	6 (11.5)	
Unidirectional	96 (79.3)	66 (95.7)	30 (57.7)	
Vertical	3 (2.5)	0	3 (5.8)	
Isolated torsional	3 (2.5)	0	3 (5.8)	
Bidirectional	10 (8.3)	0	10 (19.2)	
Skew deviation, n (%)	7 (5.8)	0	7 (13.5)	0.002
HINTS-central, n (%)	46 (38.0)	0	46 (88.5)	<0.001
Truncal ataxia, n (%)				<0.001
Grade 0	35 (28.9)	29 (42.0)	6 (11.5)	
Grade 1	40 (33.1)	36 (52.2)	4 (7.7)	
Grade 2	13 (10.7)	4 (5.8)	9 (17.3)	
Grade 3	33 (27.3)	0	33 (63.5)	
ABCD <sup>2</sup> score, median (IQR)	3 (2, 4)	2 (2, 3)	4 (3, 5)	<0.001

HINTS, head impulse-nystagmus-test of skew; HIT, head impulse test; PCS, posterior circulation stroke; VN, vestibular neuritis.

**Table 3** Sensitivity and specificity of HINTS, ABCD<sup>2</sup> and truncal ataxia in the differentiation of PCS with VN

Variables	Sensitivity, % (95% CI)	Specificity, % (95% CI)	Positive predictive value, % (95% CI)	Negative predictive value, % (95% CI)
HINTS	88.5 (75.9% to 95.2%)	100.0 (93.4% to 100.0%)	100.0 (90.3% to 100.0%)	92.0 (82.8% to 96.7%)
HINTS with nystagmus	89.1 (75.6% to 95.9%)	100.0 (93.1% to 100.0%)	100.0 (89.3% to 100.0%)	93.0 (83.7% to 97.4%)
ABCD <sup>2</sup> ≥3	90.4 (78.2% to 96.4%)	52.2 (39.9% to 64.2%)	58.8 (47.2% to 69.5%)	87.8 (73.0% to 95.4%)
ABCD <sup>2</sup> ≥4	69.2 (54.7% to 80.9%)	84.1 (72.8% to 91.4%)	76.6 (61.6% to 87.2%)	78.4 (67.0% to 86.8%)
Truncal ataxia (3)	63.5 (48.9% to 76.0%)	100.0 (93.4% to 100.0%)	100 (87.0% to 100.0%)	78.4 (68.1% to 86.2%)
Truncal ataxia (2 and 3)	80.8 (67.0% to 89.9%)	94.2 (85.1% to 98.1%)	91.3 (78.3% to 97.2%)	86.7 (76.4% to 93.1%)

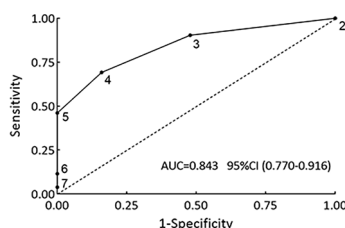
HINTS, head impulse-nystagmus-test of skew; PCS, posterior circulation stroke; VN, vestibular neuritis.

64.2%). The sensitivity of ABCD<sup>2</sup> score ≥4 was 69.2% (95% CI 54.7% to 80.9%) and the specificity was 84.1% (95% CI 72.8% to 91.4%) (table 3).

### Bedside HINTS plus ABCD<sup>2</sup> or truncal ataxia in identifying PCS

We combined HINTS and ABCD<sup>2</sup> score or truncal ataxia to improve the performance of HINTS (table 4). HINTS plus ABCD<sup>2</sup> score ≥3 reached a higher sensitivity of 98.1% (95% CI 88.4% to 99.9%) but a lower specificity of 52.2% (95% CI 39.9% to 64.2%). Simultaneously, HINTS plus ABCD<sup>2</sup> score ≥4 showed a higher sensitivity of 96.2% (95% CI 85.7% to 99.3%) but a lower specificity of 76.6% (95% CI 61.6% to 87.2%).

Furthermore, the sensitivity also increased when truncal ataxia was added to the HINTS assessment. HINTS plus grade 3 truncal ataxia reached a higher sensitivity of 98.1% (95% CI 88.4% to 99.9%), and the specificity remained at 100.0% (95% CI 93.4% to 100.0%). Notably, HINTS plus grade 2–3 truncal ataxia showed a higher sensitivity of 100.0% (95% CI 91.4% to 100.0%), and the specificity was slightly reduced to 94.2% (95% CI 85.1% to 98.1%). Comparisons of HINTS and its combinations are shown in figure 3A. The sensitivity was significantly improved in combination with grade 2–3 truncal ataxia compared with that of isolated HINTS ( $p=0.031$ ), while the specificity did not differ ( $p=0.125$ ). However, other combination patterns did not significantly increase the sensitivity of HINTS ( $p>0.05$ ).



**Figure 2** Receiver operating characteristic curve of the ABCD<sup>2</sup> score to differentiate PCS from VN. Each of the ABCD<sup>2</sup> score (2–7) was indicated on the curve. AUC, area under the curve; PCS, posterior circulation stroke; VN, vestibular neuritis.

### ABCD<sup>2</sup> plus truncal ataxia in identifying PCS

ABCD<sup>2</sup> ≥4 plus grade 2–3 truncal ataxia yielded a sensitivity of 94.2% (95% CI 83.1% to 98.5%) and specificity of 81.2% (95% CI 69.6% to 89.2%) in differentiating PCS from VN (table 4). Compared with isolated ABCD<sup>2</sup> score ≥4 or isolate grade 2–3 truncal ataxia, ABCD<sup>2</sup> score ≥4 plus grade 2–3 truncal ataxia reached a significantly higher sensitivity ( $p=0.016$  and  $p<0.001$ , respectively) (figure 3B). The sensitivity between ABCD<sup>2</sup> score ≥4 plus grade 2–3 truncal ataxia and HINTS did not statistically differ ( $p=0.508$ ). While the specificity of ABCD<sup>2</sup> score ≥4 plus grade 2–3 truncal ataxia was lower than that for HINTS ( $p<0.001$ ).

The sensitivity of ABCD<sup>2</sup> ≥4 for stroke varied by age (18–39 years, 28.6%; 40–59 years, 50.0%; ≥60 years, 92.6%) (online supplemental table 2), while that of ABCD<sup>2</sup> ≥4 plus grade 2–3 truncal ataxia substantially decreased to 85.7% (95% CI 42.0% to 99.2%) in the young patients aged <40 years old. For those ≥60 years, the sensitivity was highest at 100.0% (95% CI 84.5% to 100.0%).

### DISCUSSION

In the current analysis, we combined HINTS with grade 2–3 truncal ataxia and achieved significantly higher sensitivity than that of isolated HINTS. Additionally, ABCD<sup>2</sup> score ≥4 plus grade 2–3 truncal ataxia exhibited comparable sensitivity to that of HINTS but lower specificity, both of which were notably impacted by the patient's age.

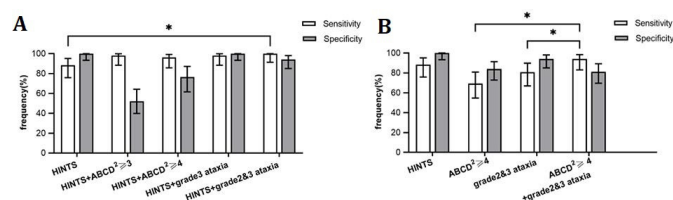
HINTS could reach a sensitivity of 97.9%–100% and a specificity of 65.4%–96% in distinguishing stroke from AVS.<sup>4 23</sup> The specificity of HINTS reached 100% in our study, marginally higher than that previously reported. The potential occurrence of false negatives in peripheral-HINTS during VN diagnosis was attributed to 5% (4/72) to 10% (1/10) of patients with VN exhibiting skew deviation.<sup>12 24</sup> However, we found no skew deviation in VN patients. A mild degree of skew deviation was difficult to detect in the presence of spontaneous nystagmus,<sup>4</sup> and the onset time at enrollment surpassed that of prior studies, leading to the elimination of skew deviation in VN patients.

**Table 4** Sensitivity and specificity of combination of ABCD<sup>2</sup>, truncal ataxia and HINTS in the differentiation of PCS with VN

Variables	Sensitivity, % (95% CI)	Specificity, % (95% CI)	Positive predictive value, % (95% CI)	Negative predictive value, % (95% CI)
HINTS plus ABCD <sup>2</sup> ≥3	98.1 (88.4% to 99.9%)	52.2 (39.9% to 64.2%)	60.7 (49.4% to 71.0%)	97.3 (84.2% to 99.9%)
HINTS plus ABCD <sup>2</sup> ≥4	96.2 (85.7% to 99.3%)	76.6 (61.6% to 87.2%)	82.0 (69.6% to 90.2%)	94.7 (80.9% to 99.1%)
HINTS plus truncal ataxia (3)	98.1 (88.4% to 99.9%)	100.0 (93.4% to 100.0%)	100.0 (91.3% to 100.0%)	98.6 (91.2% to 99.9%)
HINTS plus truncal ataxia (2 and 3)	100.0 (91.4% to 100.0%)	94.2 (85.1% to 98.1%)	92.9 (81.9% to 97.7%)	100.0 (93.0% to 100.0%)
ABCD <sup>2</sup> ≥4 plus truncal ataxia (2 and 3)	94.2 (83.1% to 98.5%)	81.2 (69.6% to 89.2%)	79.0 (66.5% to 87.9%)	94.9 (84.9% to 98.7%)

HINTS, head impulse-nystagmus-test of skew; PCS, posterior circulation stroke; VN, vestibular neuritis.

Similar to previous studies,<sup>4,20</sup> herein, HINTS identified 46 of 52 patients with PCS with a high sensitivity of approximately 90%. Among the six unrecognised patients, five had infarcts located in the AICA territory, while one had a large cerebellar infarct located in the PICA territory with a mass effect on cerebellopontine angle structure, consistent with the cause of false negatives in central HINTS reported in previous studies.<sup>6,12,25</sup> Truncal ataxia provided valuable insights for identifying PCS in acutely dizzy patients.<sup>11,12</sup> Previous studies reported severe truncal ataxia frequently presented in central AVS,<sup>4,6</sup> while isolated grade 2-3 truncal ataxia showed a sensitivity and specificity of 66.7%–92.2% and 61.1%–67.0%, respectively, in distinguishing stroke.<sup>11,12</sup> Isolated grade 2-3 truncal ataxia had a higher specificity in our study, which could be explained by the longer onset period, rapid alleviation of truncal ataxia, and lower proportion of severe truncal ataxia observed in VN patients. The six unrecognised patients with PCS by isolated HINTS had grade 2-3 truncal ataxia. Therefore, HINTS plus grade 2-3 truncal ataxia reached a sensitivity of 100%, significantly higher than that of isolated HINTS. Carmona *et al* combined truncal ataxia with three signs of HINTS and achieved a 100% sensitivity,<sup>12</sup> which was in accordance with our findings.



**Figure 3** (A) Sensitivity and specificity of HINTS and its combinations with ABCD<sup>2</sup> score or truncal ataxia. (B) Sensitivity and specificity of HINTS, ABCD<sup>2</sup>≥4, grade 2-3 truncal ataxia and ABCD<sup>2</sup>≥4 plus grade 2-3 truncal ataxia. \*Significantly different at  $p<0.05$  (McNemar test). Error bars show 95% CI. HINTS, head impulse-nystagmus-test of skew.

However, HINTS plus ABCD<sup>2</sup> score did not significantly improve HINTS in our study. Another two studies demonstrated that HINTS plus ABCD<sup>2</sup> ≥4 significantly elevated the accuracy for detecting stroke in general acutely dizzy patients.<sup>20,25</sup> ABCD<sup>2</sup> score was a simple approach to stratify stroke risk following TIA,<sup>26</sup> with diagnostic efficacy in identifying cerebrovascular causes of dizziness in the ER.<sup>15</sup> In patients with dizziness, ABCD<sup>2</sup> score improved the accuracy of HINTS by distinguishing non-stroke central pathology.<sup>20</sup> However, we only enrolled patients with PCS and VN and not those with non-stroke central lesions, which could be the reason for the lack of improvement in HINTS plus ABCD<sup>2</sup> score.

HINTS was largely dependent on the presence of oculomotor abnormalities. A previous study demonstrated that excluding patients without nystagmus improved the accuracy of HINTS.<sup>20</sup> Central HINTS reached a slightly higher sensitivity in the subgroup with nystagmus in our study (from 88.5% to 89.1%). Among the nine (7.4%, 9/121) patients without nystagmus, six had PCS and three had VN. Five of the six patients with PCS had grade 2-3 truncal ataxia, while the three patients with VN had grade 0 truncal ataxia. Isolated acute truncal ataxia without nystagmus had a prevalence of 8%–17% in patients with acute vertigo and was closely correlated with central vestibular pathology.<sup>27</sup> Therefore, truncal ataxia evaluation could also help identify PCS in the absence of nystagmus, while HINTS might not be applicable.

Due to inadequate awareness, absence of specific training and lack of confidence in performing or interpreting the examination accurately in primary-level and remote medical centres, HINTS was significantly underused in the ER.<sup>8,9,28</sup> Both ABCD<sup>2</sup> and truncal ataxia allowed for easier evaluation without the need for additional expert training. We combined the two simple assessments to distinguish PCS. Compared with HINTS, ABCD<sup>2</sup> score ≥4 plus grade 2-3 truncal ataxia reached a slightly higher sensitivity but lower specificity. However, while ABCD<sup>2</sup> score plus truncal ataxia was highly sensitive



and valuable in identifying PCS, its lower specificity could lead to excessive examinations or incorrect therapies such as tPA or antiplatelet agents and subsequent risks. The decreased sensitivity of ABCD<sup>2</sup> score in young patients would restrict its generalisation. It was necessary to consider truncal ataxia with ABCD<sup>2</sup> score in real clinical scenarios comprehensively. Therefore, HINTS remained the gold-standard assessment and every effort must be made to learn how to perform and interpret it, as recommended by the GRACE-3 guideline.<sup>29</sup> The rate at which physicians at varying clinical levels acquired proficiency in HINTS varied. Indeed, Gerlier *et al* found that senior ER physicians could use HINTS proficiently after training for a 6-hour training session.<sup>23</sup> However, another study found that neurology interns required more than 2 years to perform reliable HINTS.<sup>11</sup> It was imperative to offer more training to junior-ranking and primary-level physicians in the future.

There were still a few limitations to our study. First, this was a single-centre study with a small sample size. Multi-centre studies with larger-sample sizes were warranted to verify our findings. Furthermore, the patients enrolled in our study had a longer time (<7 days) from symptom onset. Occurrence of oedema and changes in symptoms or signs over time might have affected our results. Nevertheless, our results could be applicable to a population with a wider onset time.

## CONCLUSION

Compared with the ABCD<sup>2</sup> score, truncal ataxia is of more valuable assistance to the HINTS examination in differentiating PCS. The combination of the ABCD<sup>2</sup> score and truncal ataxia has significant implication; however, it is not a replacement for HINTS.

## Author affiliations

<sup>1</sup>Department of Neurology, Beijing Tiantan Hospital, Capital Medical University, Beijing, China

<sup>2</sup>China National Clinical Research Center for Neurological Diseases, Beijing, China

<sup>3</sup>Clinical Center for Vertigo and Balance Disturbance, Beijing Tiantan Hospital, Capital Medical University, Beijing, China

<sup>4</sup>Research Unit of Artificial Intelligence in Cerebrovascular Disease, Chinese Academy of Medical Sciences, Beijing, China

<sup>5</sup>Beijing Institute of Brain Disorders, Collaborative Innovation Center for Brain Disorders, Capital Medical University, Beijing, China

**Acknowledgements** We would like to thank Editage (www.editage.cn) for English language editing.

**Contributors** XL performed the statistics analysis and drafted the original manuscript. ZL and YJ contributed to conducting clinical examinations and collecting medical records. XZ conceived and designed the research and acted as guarantor. Fundings were obtained from YJ and XZ. All authors revised and agreed to be accountable for the content of work. XL and ZL shared first authorship.

**Funding** This work was supported by grants from the Beijing Municipal Committee of Science and Technology (Z201100005620010), Chinese Academy of Medical Sciences clinical and translational medicine (2022-I2M-C&T-B-116), Chinese Academy of Medical Sciences Innovation Fund for Medical Sciences (2019-I2M-5-029), Ministry of Finance of the People's Republic of China (issued by Finance and Social Security (2015) Document No. 82; (2016) Document No. 50; (2017) Document No. 72; (2018) Document No. 48; (2019) Document No. 77; (2020)

Document No. 75; (2021) Document No. 84, Ministry of Finance and the National Key R&D Program of China (2022ZD0118005).

**Competing interests** None declared.

**Patient consent for publication** Not applicable.

**Ethics approval** This study involves human participants and was approved by Ethics Committee in Beijing Tiantan Hospital (KY2022-046-02). Participants gave informed consent to participate in the study before taking part.

**Provenance and peer review** Not commissioned; externally peer reviewed.

**Data availability statement** Data are available on reasonable request. The datasets used or analysed during the current study are available from the corresponding author on reasonable request.

**Supplemental material** This content has been supplied by the author(s). It has not been vetted by BMJ Publishing Group Limited (BMJ) and may not have been peer-reviewed. Any opinions or recommendations discussed are solely those of the author(s) and are not endorsed by BMJ. BMJ disclaims all liability and responsibility arising from any reliance placed on the content. Where the content includes any translated material, BMJ does not warrant the accuracy and reliability of the translations (including but not limited to local regulations, clinical guidelines, terminology, drug names and drug dosages), and is not responsible for any error and/or omissions arising from translation and adaptation or otherwise.

**Open access** This is an open access article distributed in accordance with the Creative Commons Attribution Non Commercial (CC BY-NC 4.0) license, which permits others to distribute, remix, adapt, build upon this work non-commercially, and license their derivative works on different terms, provided the original work is properly cited, appropriate credit is given, any changes made indicated, and the use is non-commercial. See: <http://creativecommons.org/licenses/by-nc/4.0/>.

## ORCID iD

Xingquan Zhao <http://orcid.org/0000-0001-8345-5147>

## REFERENCES

- Kerber KA. Acute vestibular syndrome. *Semin Neurol* 2020;40:059–66.
- Kim JS, Lee H. Vertigo due to posterior circulation stroke. *Semin Neurol* 2013;33:179–84.
- Choi J-H, Kim H-W, Choi K-D, *et al*. Isolated vestibular syndrome in posterior circulation stroke: frequency and involved structures. *Neurol Clin Pract* 2014;4:410–8.
- Kattah JC, Talkad AV, Wang DZ, *et al*. HINTS to diagnose stroke in the acute vestibular syndrome: three-step bedside oculomotor examination more sensitive than early MRI diffusion-weighted imaging. *Stroke* 2009;40:3504–10.
- Perry JJ, Newman-Toker DE, Ohle R. The HINTS exam is a skill emergency physicians need to learn, apply and master. *Can J Emerg Med* 2022;24:679–81.
- Tarnutzer AA, Gold D, Wang Z, *et al*. Impact of clinician training background and stroke location on bedside diagnostic test accuracy in the acute vestibular syndrome - a meta-analysis. *Ann Neurol* 2023;94:295–308.
- Ohle R, Montpellier R-A, Marchadier V, *et al*. Can emergency physicians accurately rule out a central cause of vertigo using the HINTS examination? A systematic review and meta-analysis. *Acad Emerg Med* 2020;27:887–96.
- McDowell T, Moore F. The under-utilization of the head impulse test in the emergency department. *Can J Neurol Sci* 2016;43:398–401.
- Warner CL, Bunn L, Koohi N, *et al*. Clinician's perspectives in using head impulse-nystagmus-test of Skew (HINTS) for acute vestibular syndrome: UK experience. *Stroke Vasc Neurol* 2022;7:172–5.
- Kattah JC, Zalazar G, Martinez C, *et al*. Truncal ataxia and the vestibulo spinal reflex. A historical review. *J Neurol Sci* 2022;441:120375.
- Kattah JC, Martinez C, Zalazar G, *et al*. Role of Incubitus truncal ataxia, and equivalent standing grade 3 ataxia in the diagnosis of central acute vestibular syndrome. *J Neurol Sci* 2022;441:120374.
- Carmona S, Martínez C, Zalazar G, *et al*. The diagnostic accuracy of truncal ataxia and HINTS as cardinal signs for acute vestibular syndrome. *Front Neurol* 2016;7:125.
- Yang J, Fu J-H, Chen X-Y, *et al*. Validation of the ABCD<sup>2</sup> score to identify the patients with high risk of late stroke after a transient ischemic attack or minor ischemic stroke. *Stroke* 2010;41:1298–300.
- Johnston SC, Rothwell PM, Nguyen-Huynh MN, *et al*. Validation and refinement of scores to predict very early stroke risk after transient ischaemic attack. *The Lancet* 2007;369:283–92.

- 15 Navi BB, Kamel H, Shah MP, *et al.* Application of the ABCD<sup>2</sup> score to identify cerebrovascular causes of dizziness in the emergency Department. *Stroke* 2012;43:1484–9.
- 16 Newman-Toker DE, Kerber KA, Hsieh Y-H, *et al.* HINTS Outperforms ABCD<sup>2</sup> to screen for stroke in acute continuous vertigo and dizziness. *Acad Emerg Med* 2013;20:986–96.
- 17 Lou H, Dong Z, Zhang P, *et al.* Interaction of diabetes and smoking on stroke: a population-based cross-sectional survey in China. *BMJ Open* 2018;8:e017706.
- 18 Halmagyi GM, Curthoys IS. A clinical sign of canal paresis. *Archives of Neurology* 1988;45:737–9.
- 19 Kerber KA, Meurer WJ, Brown DL, *et al.* Stroke risk stratification in acute dizziness presentations: a prospective imaging-based study. *Neurology* 2015;85:1869–78.
- 20 Wang W, Zhang Y, Pan Q, *et al.* Central nystagmus plus ABCD(2) identifying stroke in acute dizziness presentations. *Acad Emerg Med* 2021;28:1118–23.
- 21 Strupp M, Bisdorff A, Furman J, *et al.* Acute unilateral vestibulopathy/ vestibular neuritis: diagnostic criteria. *J Vestib Res* 2022;32:389–406.
- 22 Hazra A, Gogtay N. Biostatistics series module 4: comparing groups - categorical variables. *Indian J Dermatol* 2016;61:385–92.
- 23 Gerlier C, Hoarau M, Fels A, *et al.* Differentiating central from peripheral causes of acute vertigo in an emergency setting with the HINTS, STANDING, and Abcd2 tests: a diagnostic cohort study. *Acad Emerg Med* 2021;28:1368–78.
- 24 Chen L, Lee W, Chambers BR, *et al.* Diagnostic accuracy of acute vestibular syndrome at the bedside in a stroke unit. *J Neurol* 2011;258:855–61.
- 25 Kmetonyova S, Paulasova Schwabova J, Sramkova T, *et al.* Posterior circulation stroke diagnosis in unselected group of acutely dizzy patients. *Clin Neurol Neurosurg* 2023;224:107541.
- 26 Carpenter CR, Keim SM, Crossley J, *et al.* Post-transient ischemic attack early stroke stratification: the ABCD(2) Prognostic aid. *J Emerg Med* 2009;36:194–8.
- 27 Carmona S, Martínez C, Zalazar G, *et al.* Acute Truncal ataxia without nystagmus in patients with acute vertigo. *Eur J Neurol* 2023;30:1785–90.
- 28 Quimby AE, Kwok ESH, Lelli D, *et al.* Usage of the HINTS exam and neuroimaging in the assessment of peripheral vertigo in the emergency department. *J Otolaryngol Head Neck Surg* 2018;47:54.
- 29 Edlow JA, Carpenter C, Akhter M, *et al.* Guidelines for reasonable and appropriate care in the emergency department 3 (GRACE-3): acute dizziness and vertigo in the emergency department. *Acad Emerg Med* 2023;30:442–86.