



# Aetiology of extracranial carotid free-floating thrombus in a prospective multicentre cohort

Dar Dowlatshahi <sup>1,2,3</sup>, Cheemun Lum,<sup>4</sup> Bijoy K Menon,<sup>5</sup> Aditya Bharatha,<sup>6</sup> Prasham Dave,<sup>7</sup> Paulo Puac-Polanco,<sup>4</sup> Dylan Blacquiere,<sup>1</sup> Grant Stotts,<sup>1</sup> Michel Shamy,<sup>1,2,3</sup> Franco Momoli,<sup>3</sup> Rebecca Thornhill,<sup>4</sup> Ronda Lun <sup>1</sup>, Carlos Torres<sup>4</sup>

**To cite:** Dowlatshahi D, Lum C, Menon BK, *et al.* Aetiology of extracranial carotid free-floating thrombus in a prospective multicentre cohort. *Stroke & Vascular Neurology* 2023;**8**: e001639. doi:10.1136/svn-2022-001639

► Additional supplemental material is published online only. To view, please visit the journal online (<http://dx.doi.org/10.1136/svn-2022-001639>).

Received 9 April 2022  
Accepted 19 October 2022  
Published Online First  
11 November 2022

## ABSTRACT

**Background** Carotid free-floating thrombi (FFT) in patients with acute transient ischaemic attack (TIA)/stroke have a high risk of early recurrent stroke. Management depends on aetiology, which can include local plaque rupture, dissection, coagulopathy, malignancy and cardioembolism. Our objectives were to classify the underlying aetiology of FFT and to estimate the proportion of patients with underlying stenosis requiring revascularisation.

**Methods** We prospectively enrolled consecutive patients presenting to three comprehensive stroke centres with acute TIA/stroke and ipsilateral internal carotid artery FFT. The aetiology of FFT was classified as: carotid atherosclerotic disease, carotid dissection, cardioembolism, both carotid atherosclerosis and cardioembolism, or embolic stroke of uncertain source (ESUS). Patients with carotid atherosclerosis were further subclassified as having  $\geq 50\%$  or  $< 50\%$  stenosis.

**Results** We enrolled 83 patients with confirmed FFT. Aetiological assessments revealed 66/83 (79.5%) had carotid atherosclerotic plaque, 4/83 (4.8%) had a carotid dissection, 10/83 (12%) had both atrial fibrillation and carotid atherosclerotic plaque and 3/83 (3.6%) were classified as ESUS. Of the 76 patients with atherosclerotic plaque (including those with atrial fibrillation), 40 (52.6%) had  $\geq 50\%$  ipsilateral stenosis.

**Conclusions** The majority of symptomatic carotid artery FFT are likely caused by local plaque rupture, more than half of which are associated with moderate to severe carotid stenosis requiring revascularisation. However, a significant number of FFTs are caused by non-atherosclerotic mechanisms warranting additional investigations.

## INTRODUCTION

Carotid free-floating thrombi (FFT) are present in 1.6%–3.7% of patients presenting with acute transient ischaemic attack (TIA)/stroke.<sup>1</sup> While relatively uncommon, FFT are high-risk lesions with an approximately 11% risk of stroke or death within 30 days of diagnosis.<sup>2</sup> Immediate management typically consists of antithrombotic medications,<sup>1</sup> although there is no consensus on the optimal therapeutic agent or duration of therapy.

## WHAT IS ALREADY KNOWN ON THIS TOPIC

- ⇒ Carotid free-floating thrombi (FFT) are high risk for stroke recurrence.
- ⇒ Carotid FFT are associated with local plaque rupture.

## WHAT THIS STUDY ADDS

- ⇒ Up to 40% of carotid FFT have associated stenosis requiring revascularisation.
- ⇒ Up to 20% of carotid FFT have a non-atherosclerotic aetiology.

## HOW THIS STUDY MIGHT AFFECT RESEARCH, PRACTICE OR POLICY

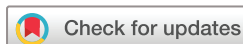- ⇒ Carotid FFT require investigation for non-atherosclerotic aetiologies.

The majority of FFT are believed to originate from local atherosclerotic plaque rupture. Moreover, many are associated with a significant degree of underlying carotid stenosis.<sup>1</sup> However, FFT are also reported in association with dissections, coagulopathy and malignancy, and can be associated with cardioembolism.<sup>1,3,4</sup> The relative proportion of atherosclerotic versus non-atherosclerotic causes of FFT is unknown.

Our primary objective was to explore and classify the underlying aetiology of carotid thrombi in a well-characterised consecutive, prospective, multicentre cohort of patients presenting with TIA/stroke symptoms and confirmed ipsilateral FFT. Our secondary objective was to characterise the degree of underlying stenosis when the FFT was associated with local atherosclerotic plaque.

## METHODS

We prospectively enrolled consecutive patients presenting to the emergency departments of the Ottawa Hospital (Ottawa, Canada), Calgary Foothills Hospital (Calgary, Canada) and St. Michael's Hospital (Toronto, Canada) with a diagnosis of acute TIA/stroke



© Author(s) (or their employer(s)) 2023. Re-use permitted under CC BY-NC. No commercial re-use. See rights and permissions. Published by BMJ.

For numbered affiliations see end of article.

## Correspondence to

Dr Dar Dowlatshahi;  
ddowlat@toh.ca

within 24 hours of symptom onset. Details of the study (ClinicalTrials.gov NCT02405845) are published elsewhere.<sup>5</sup> Patients were enrolled if the CT angiography (CTA) at presentation revealed an ipsilateral internal carotid artery (ICA) lesion suspected to represent an FFT, based on the appearance of an intraluminal filling defect. Diagnosis of FFT was confirmed by either the resolution or decrease in size of the filling defect seen on serial CTA, based on consensus review by two neuroradiologists, or intraoperative pathology during carotid endarterectomy. Antithrombotic therapy and the timing of repeat clinical CTAs were at the discretion of the treating physician. In patients where no resolution or decrease in size of the filling defect was observed on CTAs in the first month, a CTA was performed at 5 weeks following symptom onset, as per study protocol; if the lesion was unchanged on this repeat CTA, it was deemed not to be FFT. The threshold of 5 weeks was chosen a priori based on prior work demonstrating that all confirmed FFT decreased in size within 3 weeks of symptom onset.<sup>6</sup>

The aetiology of FFT was determined based on imaging appearance and medical record review as: (1) carotid atherosclerotic disease if there was residual plaque identified on follow-up CTA imaging directly adjacent to, or in contact with the filling defect after FFT resolution, and with no other potential cause identified; (2) carotid dissection; (3) cardioembolism if no adjacent plaque or dissection was identified after resolution and cardiac testing revealed atrial fibrillation or any other known cardiac source; (4) possible carotid atherosclerosis or cardioembolism where both adjacent plaque and a known cardiac source were discovered or (5) embolic stroke of uncertain source (ESUS) where no ipsilateral plaque was identified and aetiological testing was unrevealing. Patients with an adjacent carotid plaque were further subclassified as having  $\geq 50\%$  or  $< 50\%$  stenosis. All imaging assessments for aetiology were by consensus of two neuroradiologists. Aetiological workup followed the Canadian Best Practice Recommendations<sup>7</sup> and included cardiac transthoracic echocardiography and ambulatory rhythm monitoring for 14 days to assess for atrial fibrillation. After completing the initial prospective study, a medical record review was conducted for any additional aetiological workup. Source data will be available on reasonable request to the lead investigators.

## RESULTS

We enrolled 100 patients with suspected FFT: 1 subject withdrew consent and 4 were excluded from the study due to protocol deviations (3 patients did not have a repeat CTA to confirm FFT, and 1 patient was erroneously enrolled with a vertebral artery thrombus). Detailed information on the full study cohort is published elsewhere.<sup>5</sup> Eighty-three patients had confirmed FFT on follow-up imaging (median confirmatory follow-up scan at 4 days) and were included in our analysis (table 1). Two patients

**Table 1** Baseline characteristics of patients confirmed to have a carotid free-floating thrombus

N=83	
Baseline characteristics	
Age at presentation (mean $\pm$ SD)	67.2 $\pm$ 14.0
Female sex (n,%)	30 (36.1)
Medical history	
Coronary artery disease (n,%)	14 (16.9)
Myocardial infarction (n,%)	13 (15.7)
Ischaemic stroke (n,%)	15 (18.3)
Atrial fibrillation (n,%)	8 (9.6)
Venous thromboembolism (n,%)	5 (6.0)
Diabetes mellitus (n,%)	15 (18.1)
Dyslipidaemia (n,%)	38 (45.8)
Hypertension (n,%)	46 (55.4)
Medication use	
Prior anticoagulant use (n,%)	9 (10.8)
Prior antiplatelet use (n,%)	26 (31.3)
Clinical presentation	
Stroke (n,%)	68 (81.9)
Transient ischaemic attack (n,%)	15 (18.1)
Treatment	
Single antiplatelet	3 (3.6)
Dual antiplatelet	19 (22.9)
Anticoagulation	38 (45.8)
Anticoagulation and antiplatelet	20 (24.1)
None	3 (3.6)

experienced recurrent events: one TIA and one stroke requiring thrombectomy.<sup>5</sup>

Aetiological assessment revealed that 66/83 (79.5%) patients had an underlying adjacent atherosclerotic plaque. Another 10/83 (12%) had both atrial fibrillation and adjacent atherosclerotic plaque, 4/83 (4.8%) had a carotid dissection, 3/83 (3.6%) were classified as ESUS and no patient had atrial fibrillation in the absence of adjacent plaque. Of the 76 patients with adjacent atherosclerotic disease (including those with atrial fibrillation), 40 (52.6%) had  $\geq 50\%$  ipsilateral stenosis (details in online supplemental table 1). Of the four patients classified as ESUS, one was a 25-year-old patient with patent foramen ovale, and two were suspected of having hypercoagulability (one due to lung carcinoma and one related to ulcerative colitis).

## DISCUSSION

These results show that atherosclerotic plaque rupture may be the likely aetiology in at least four out of every five patients presenting with FFT and TIA/stroke. This number could be higher if it is assumed that FFT is due to plaque rupture in patients with a coexisting aetiology, that is, with both atrial fibrillation and local atherosclerotic plaque.

Moreover, over half of these patients had underlying carotid stenoses of  $\geq 50\%$  warranting urgent revascularisation, which is comparable to a recent single-centre cohort study.<sup>1</sup> These findings highlight an important knowledge gap in FFT management in the context of symptomatic carotid stenosis: should such patients be offered early revascularisation, or should there be a period of antithrombotic therapy to reduce thrombus burden prior to either endarterectomy or carotid artery stenting? Immediate treatment with the combination of anticoagulation and antiplatelet therapy is associated with partial or complete resolution of FFT in 75%–86.5% of patients within a median time of 4–6 days.<sup>1,5</sup> This must be weighed against the early recurrent stroke risk associated with delaying revascularisation for symptomatic carotid stenosis, which can be as high as 7.9% in the first week.<sup>8</sup> These two approaches may warrant further study in a comparative randomised trial.

Between 8% and 20% of patients presenting with FFT have a non-atherosclerotic aetiology in this study (with the higher number of this range based on the assumption that those with both atrial fibrillation and atherosclerosis were the result of cardio-embolism). Approximately 5% of these FFTs were secondary to carotid dissections in the acute setting, but the remaining FFTs required additional investigations to identify other aetiologies (arrhythmias, malignancies and other causes of hypercoagulability). This suggests that up to 15% of FFTs may result from a process distant from the carotid artery. Furthermore, approximately 1 of every 25 patients met the criteria for ESUS, highlighting the need for vigilance and additional investigations in the setting of FFT.

The strengths of our study include the study protocol-specified prospective consecutive enrolment, the validated FFT diagnostic criteria and the multicentre recruitment. But our study has important limitations. While atrial fibrillation was either known or discovered in 12% of patients, it is possible that its prevalence as an aetiology of FFT was underestimated. Conversely, local plaque rupture could also be underestimated as atheromatous changes below the detection threshold of CTA or atheroma proximal to the ICA could also give rise to FFT. For these reasons, we believe the estimates for FFT aetiology are likely to range from 80% to 92% for local plaque rupture and up to 16% for cardioembolism. Finally, our study did not collect information around the management of underlying carotid stenosis, therefore, we were not able to assess how the presence of FFT affected revascularisation decisions.

In summary, the majority of symptomatic carotid artery FFT are caused by local atherosclerotic plaque rupture, more than half of which are associated with moderate to severe carotid stenosis requiring revascularisation. However, FFT are also caused by non-atherosclerotic mechanisms warranting additional investigations for cardioembolism, hypercoagulability and malignancy. Where significant carotid stenosis is found with FFT, it is unclear whether urgent revascularisation or medical management is best to resolve FFT.

## Author affiliations

- <sup>1</sup>Department of Medicine, University of Ottawa, Ottawa, Ontario, Canada
- <sup>2</sup>Clinical Epidemiology, Ottawa Hospital Research Institute, Ottawa, Ontario, Canada
- <sup>3</sup>School of Epidemiology and Public Health, University of Ottawa, Ottawa, Ontario, Canada
- <sup>4</sup>Department of Radiology, University of Ottawa, Ottawa, Ontario, Canada
- <sup>5</sup>Departments of Clinical Neurosciences, Radiology and Community Health Sciences, University of Calgary, Calgary, Alberta, Canada
- <sup>6</sup>Department of Medical Imaging, University of Toronto, Toronto, Ontario, Canada
- <sup>7</sup>Medicine, Queen's University, Kingston, Ontario, Canada

**Contributors** DD and CL conceived the study. DD, CL, FM and RT designed the methodology. DD, CL, CT, AB, DB, GS, MS and BM executed the study and enrolled patients. CL, CT, PP-P, RL and RT reviewed imaging. PD, DD, RL, PP-P, RT and FM performed analyses. All authors contributed to writing. DD, CT and CL provided supervision. DD is the guarantor of the overall content.

**Funding** This study was funded by uOttawa Department of Medicine.

**Competing interests** None declared.

**Patient consent for publication** Not applicable.

**Ethics approval** This study involves human participants and was approved by REB#20150092-01H was obtained at Ottawa Health Science Network Research Ethics Board. Participants gave informed consent to participate in the study before taking part.

**Provenance and peer review** Not commissioned; externally peer reviewed.

**Data availability statement** Data are available on reasonable request.

**Supplemental material** This content has been supplied by the author(s). It has not been vetted by BMJ Publishing Group Limited (BMJ) and may not have been peer-reviewed. Any opinions or recommendations discussed are solely those of the author(s) and are not endorsed by BMJ. BMJ disclaims all liability and responsibility arising from any reliance placed on the content. Where the content includes any translated material, BMJ does not warrant the accuracy and reliability of the translations (including but not limited to local regulations, clinical guidelines, terminology, drug names and drug dosages), and is not responsible for any error and/or omissions arising from translation and adaptation or otherwise.

**Open access** This is an open access article distributed in accordance with the Creative Commons Attribution Non Commercial (CC BY-NC 4.0) license, which permits others to distribute, remix, adapt, build upon this work non-commercially, and license their derivative works on different terms, provided the original work is properly cited, appropriate credit is given, any changes made indicated, and the use is non-commercial. See: <http://creativecommons.org/licenses/by-nc/4.0/>.

## ORCID iDs

Dar Dowlatshahi <http://orcid.org/0000-0003-1379-3612>

Ronda Lun <http://orcid.org/0000-0001-8455-8201>

## REFERENCES

- 1 Singh R-J, Chakraborty D, Dey S, *et al.* Intraluminal thrombi in the Cerebro-Cephalic arteries. *Stroke* 2019;50:357–64.
- 2 Fridman SP, Lownie SP, Mandzia J. Diagnosis and management of carotid free-floating thrombus: a systematic literature review. *Int J Stroke* 2019;14:247–56.
- 3 Combe J, Poinard P, Besancenot J, *et al.* Free-Floating thrombus of the extracranial internal carotid artery. *Ann Vasc Surg* 1990;4:558–62.
- 4 Buchan A, Gates P, Pelz D, *et al.* Intraluminal thrombus in the cerebral circulation. Implications for surgical management. *Stroke* 1988;19:681–7.
- 5 Torres C, Lum C, Puac-Polanco P, *et al.* Differentiating carotid free-floating thrombus from atheromatous plaque using intraluminal filling defect length on cta: a validation study. *Neurology* 2021;97:e785–93.
- 6 Jaber A, Lum C, Stefanski P, *et al.* Computed tomography angiography intraluminal filling defect is predictive of internal carotid artery free-floating thrombus. *Neuroradiology* 2014;56:15–23.
- 7 Gladstone DJ, Lindsay MP, Douketis J, *et al.* Canadian stroke best practice recommendations: secondary prevention of stroke update 2020. *Can J Neurol Sci* 2022;49:315–37.
- 8 Johansson EP, Arnerlov C, Wester P. Risk of recurrent stroke before carotid endarterectomy: the ANSYSCAP study. *Int J Stroke* 2013;8:220–7.